

Article

# Patterns of Morphological and Microcirculatory Disorders in the Thyroid Gland Under Microelement Deficiency

O.G. Aslonov

Bukhara State Medical Institute

**Citation:** Aslonov O. G. Patterns of Morphological and Microcirculatory Disorders in the Thyroid Gland Under Microelement Deficiency. American Journal Of Bioscience And Clinical Integrity 2026, 3(4), 10-20.

Received: 13<sup>th</sup> Jan 2026  
Revised: 20<sup>th</sup> Feb 2026  
Accepted: 8<sup>th</sup> Mar 2026  
Published: 6<sup>th</sup> Apr 2024



**Copyright:** © 2026 by the authors. Submitted for open access publication under the terms and conditions of the Creative Commons Attribution (CC BY) license (<https://creativecommons.org/licenses/by/4.0/>)

**Abstract:** The study investigates morphological, morphometric, and microcirculatory changes in the thyroid gland under conditions of microelement deficiency (Mg, Fe, Se, Zn) in white outbred rats. Quantitative analysis revealed a decrease in thyroid gland mass accompanied by pronounced structural remodeling, including thickening of the capsule, reduction in capillary density and diameter, and impairment of microcirculatory function. Morphological alterations were characterized by a decrease in follicular epithelial height, redistribution of follicle size, and increased stromal component, indicating reduced secretory activity and fibrotic processes. The most severe changes were observed under combined microelement deficiency, demonstrating progressive structural and functional deterioration of the thyroid gland. The findings highlight the key role of microelements in maintaining thyroid homeostasis and provide insight into the pathogenesis of endocrine dysfunction under deficiency conditions.

**Keywords:** Thyroid Gland, Microelement Deficiency, Morphometry, Microcirculation, Apoptosis, CD95, CD163, Macrophages, Thyrocytes, Fibrosis

## Introduction

In recent decades, microelement deficiency has become a major global health concern due to its widespread prevalence and significant impact on human health. According to the World Health Organization, deficiencies of essential trace elements such as iron, zinc, and selenium affect billions of people worldwide and are associated with various metabolic and endocrine disorders [1].

The thyroid gland is particularly sensitive to microelement imbalance, as the synthesis of thyroid hormones depends on adequate levels of trace elements involved in enzymatic reactions. Studies by Michael B. Zimmermann and Petra L. Boelaert have demonstrated that deficiency of key microelements leads to structural and functional disturbances in thyroid tissue, including impaired hormone synthesis and morphological alterations [2].

Microcirculatory disturbances play a critical role in the pathogenesis of thyroid dysfunction. Reduced capillary density and perfusion result in impaired oxygen and nutrient supply to thyroid cells, contributing to tissue hypoxia and functional insufficiency. As reported by Carmine Colucci et al.

(2018), microvascular alterations are closely associated with endocrine organ remodeling and disease progression [3].

In addition to vascular changes, cellular mechanisms such as apoptosis and immune responses are essential components of thyroid tissue adaptation. Apoptosis regulates tissue homeostasis, but its excessive activation leads to loss of functional cells. At the same time, macrophages play a key role in tissue remodeling and immune regulation. According to Siamon Gordon and Fernando O. Martinez, alternatively activated (M2) macrophages are involved in tissue repair, fibrosis, and anti-inflammatory responses [4].

Despite numerous studies, the combined effects of different microelement deficiencies on thyroid morphology, microcirculation, and immune-related processes remain insufficiently understood. Therefore, comprehensive morphometric and immunohistochemical analysis represents an important approach to elucidate the mechanisms of thyroid gland adaptation and dysfunction under conditions of microelement imbalance [5].

#### **Aim of the study**

The aim of this study was to investigate morphological, morphometric, and microcirculatory changes in the thyroid gland under conditions of microelement deficiency (Mg, Fe, Se, Zn) in white outbred rats.

#### **Materials and Methods**

The study was conducted on thyroid tissue samples obtained from 6-month-old white outbred rats divided into two groups:

control group (intact animals),

experimental groups with deficiency of individual microelements (Mg, Fe, Se, Zn) and combined microelement deficiency [6].

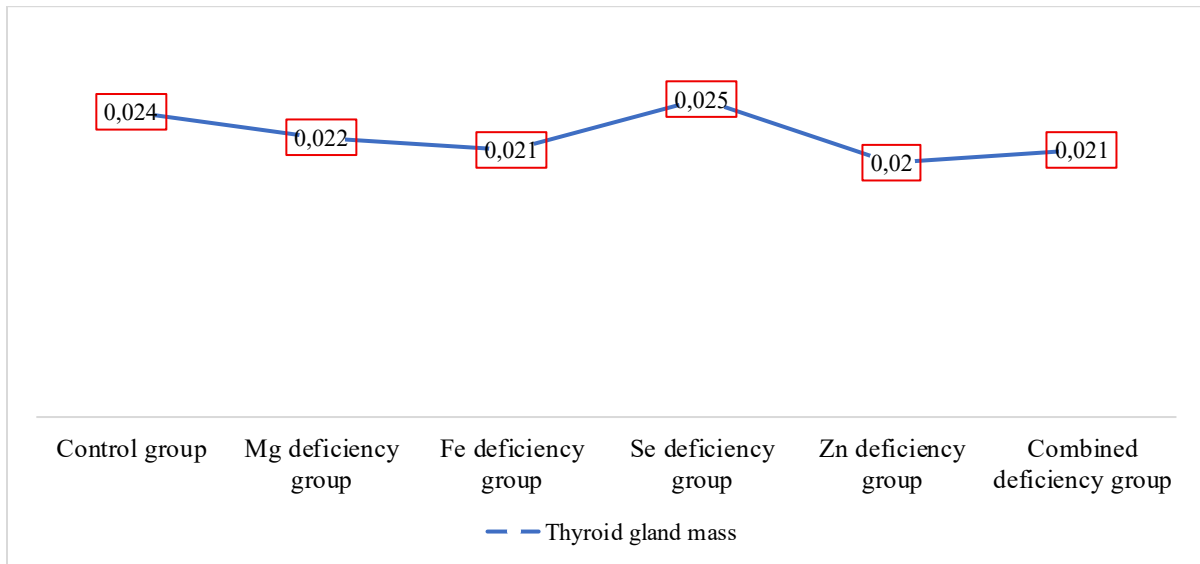
Morphological and morphometric analyses were performed to evaluate structural changes in the thyroid gland. The following parameters were assessed: thyroid gland mass, capsule thickness, capillary density, capillary diameter, total capillary cross-sectional area, relative vascular area, follicular diameter, follicular area, epithelial height, and stromal component. Microcirculatory characteristics were evaluated separately in central and peripheral regions of the gland [7].

Quantitative analysis was performed using digital morphometry with measurements expressed in relative and absolute values. Comparative analysis between groups was carried out to determine the degree of structural and functional alterations associated with different types of microelement deficiency.

Statistical analysis included calculation of relative changes compared to the control group, allowing assessment of the severity and progression of morphological alterations [8].

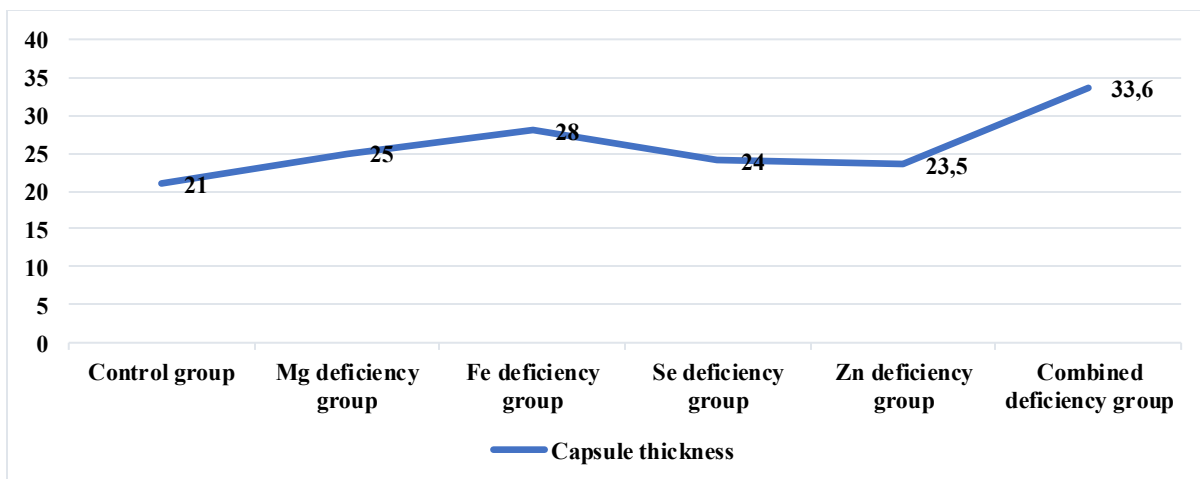
#### **Results**

Compared to the control group, thyroid gland mass decreased by 1.09 times in Mg deficiency, 1.14 times in Fe deficiency, 1.20 times in Zn deficiency, and 1.14 times in combined deficiency, while in Se deficiency it increased by 1.04 times. These findings indicate the predominance of morphological remodeling against the background of relatively stable gland mass (Fig. 1) [9].



**Figure 1.** Thyroid gland mass, g

Compared to the control group, capsule thickness increased by 1.18 times in Mg deficiency, 1.27 times in Fe deficiency, 1.34 times in Se deficiency, 1.15 times in Zn deficiency, and 1.49 times in combined deficiency. These changes reflect prolonged pathological effects and compensatory-adaptive processes in the thyroid tissue (Fig. 2) [10].



**Figure 2.** Capsule thickness, µm

Compared to the control group, capillary density in the central region decreased by 1.25 times in Mg deficiency, 1.38 times in Fe deficiency, 1.19 times in Se deficiency, 1.16 times in Zn deficiency, and 1.61 times in combined deficiency; in the peripheral region, it decreased by 1.21, 1.34, 1.18, 1.15, and 1.57 times, respectively. These findings indicate regression of the microcirculatory network and impaired capillary perfusion under conditions of microelement deficiency (Fig. 3) [11].

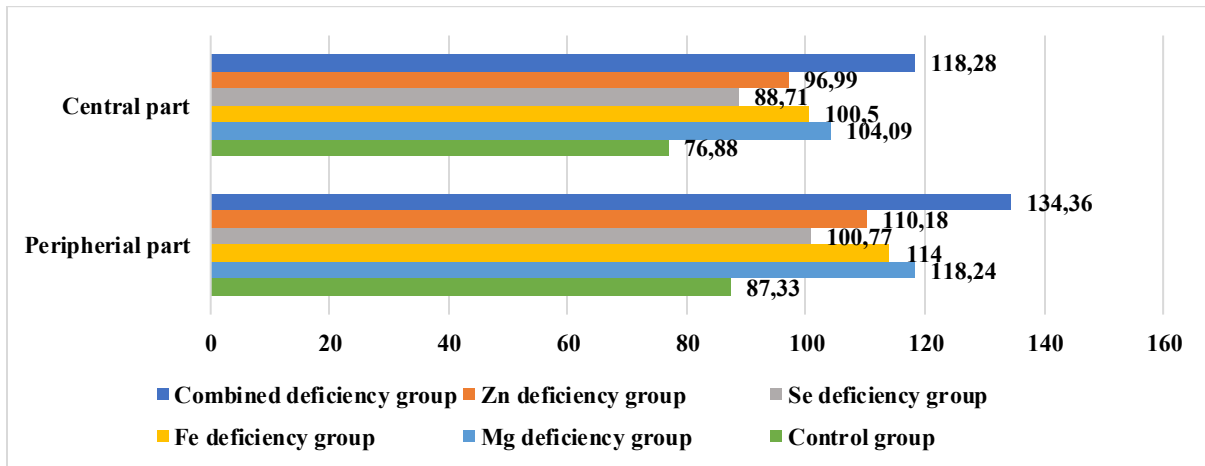


Figure 3. Capillary density, mm<sup>2</sup>

Compared to the control group, the total cross-sectional area of capillaries in the central region decreased by 1.27 times in Mg deficiency, 1.41 times in Fe deficiency, 1.22 times in Se deficiency, 1.18 times in Zn deficiency, and 1.66 times in combined deficiency; in the peripheral region, this parameter decreased by 1.24, 1.39, 1.20, 1.17, and 1.62 times, respectively. These changes reflect a reduction in the functional capacity of the capillary bed (Fig. 4) [12].

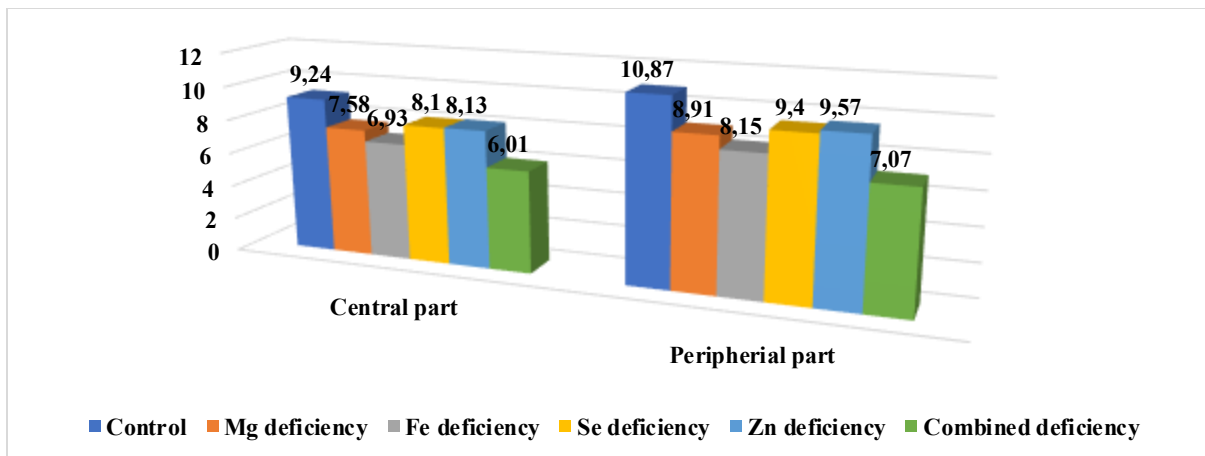


Figure 4. Total cross-sectional area of capillaries, ×10<sup>3</sup> μm<sup>2</sup>

Compared to the control group, capillary diameter in the central region decreased by 1.22 times in Mg deficiency, 1.33 times in Fe deficiency, 1.17 times in Se deficiency, 1.14 times in Zn deficiency, and 1.54 times in combined deficiency; in the peripheral region, it decreased by 1.22, 1.33, 1.19, 1.14, and 1.54 times, respectively. This reduction is characterized by narrowing of the microcirculatory vessels and impairment of hemodynamic supply to the tissues under conditions of microelement deficiency, with the most pronounced changes observed in the combined deficiency group (Fig. 5) [13].

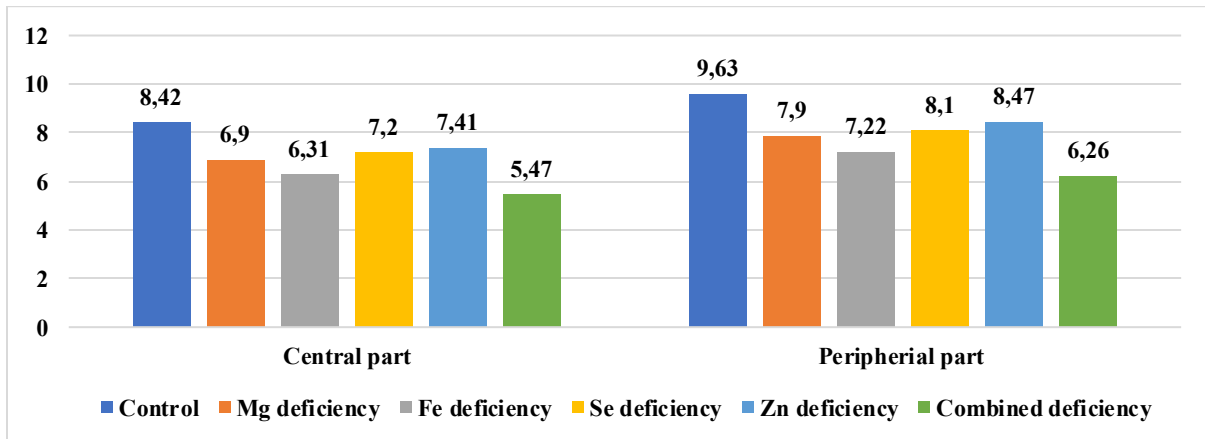


Figure 5. Capillary diameter, µm

Compared to the control group, the relative vascular area in the central region decreased by 1.23 times in Mg deficiency, 1.36 times in Fe deficiency, 1.18 times in Se deficiency, 1.15 times in Zn deficiency, and 1.58 times in combined deficiency; in the peripheral region, it decreased by 1.21, 1.33, 1.17, 1.14, and 1.54 times, respectively. These findings indicate impaired hemodynamic supply in the thyroid parenchyma (Fig. 6) [14].

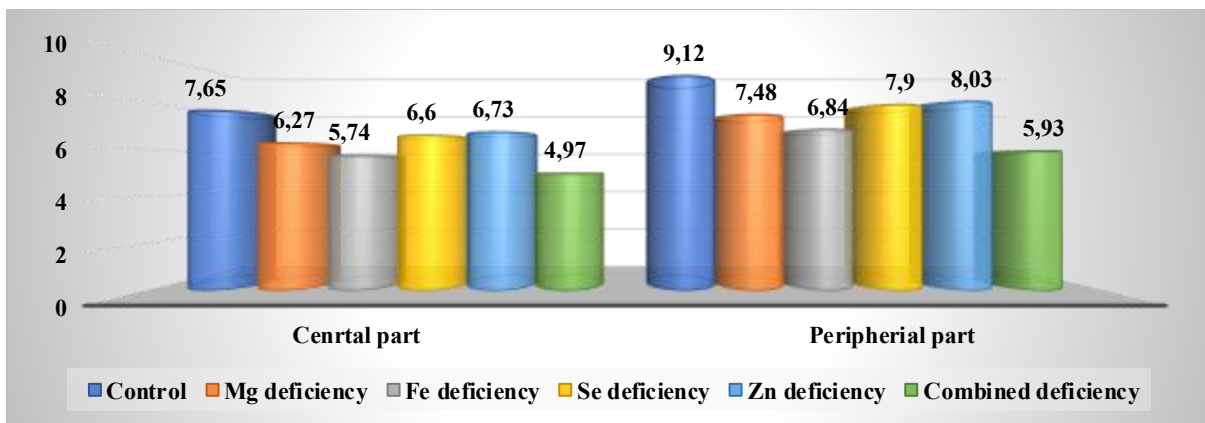
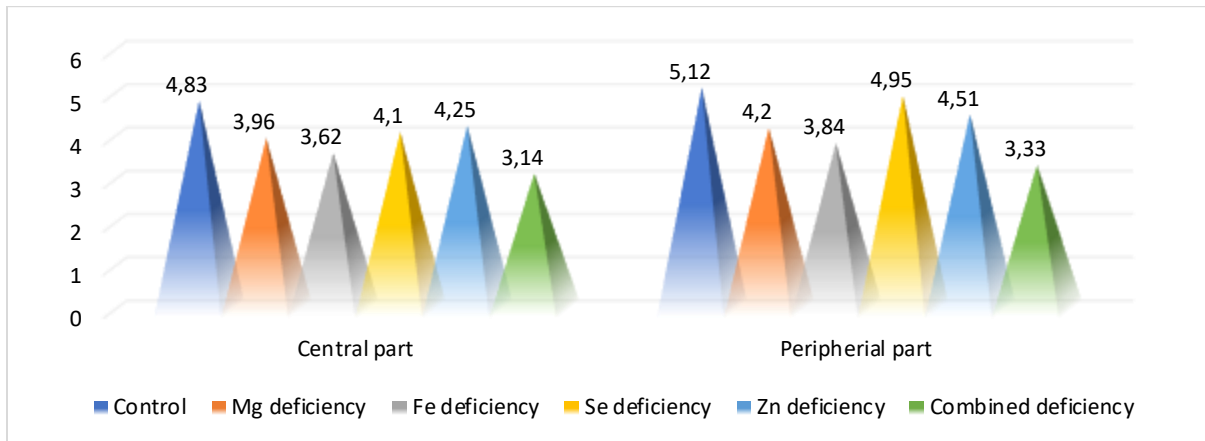


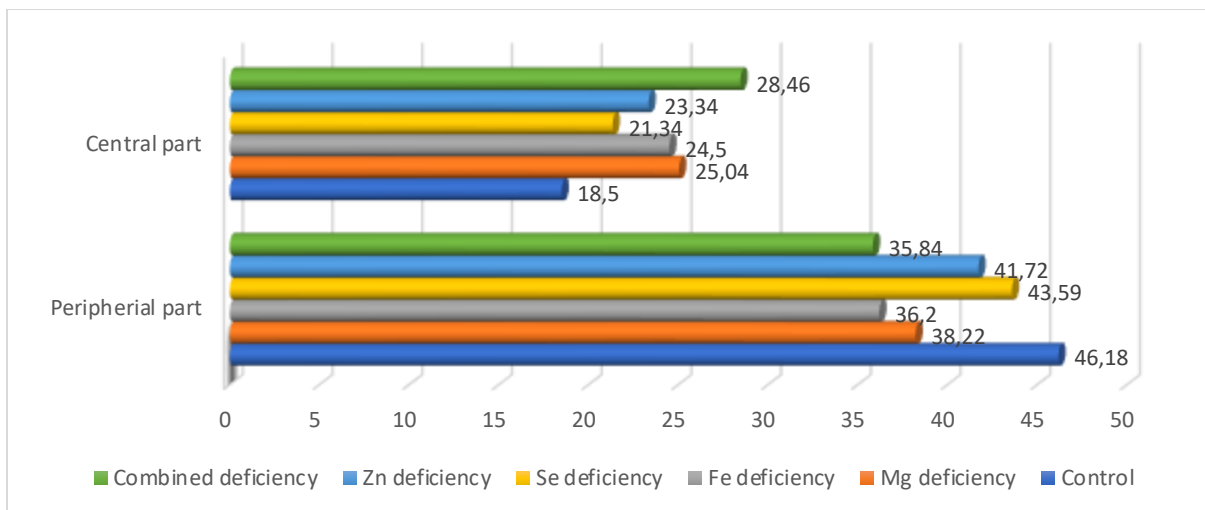
Figure 6. Relative vascular area, %

Compared to the control group, thyroid epithelial height in the central region decreased by 1.19 times in Mg deficiency, 1.31 times in Fe deficiency, 1.15 times in Se deficiency, 1.12 times in Zn deficiency, and 1.49 times in combined deficiency; in the peripheral region, it decreased by 1.10, 1.18, 1.08, 1.06, and 1.27 times, respectively. This reduction indicates decreased secretory activity of thyroid cells (Fig. 7).



**Figure 7.** Thyroid epithelial height,  $\mu\text{m}$

Compared to the control group, follicular diameter in the central region decreased by 1.14 times in Mg deficiency, 1.21 times in Fe deficiency, 1.09 times in Se deficiency, 1.07 times in Zn deficiency, and 1.32 times in combined deficiency; in the peripheral region, it increased by 1.18, 1.26, 1.12, 1.09, and 1.37 times, respectively. These changes reflect dystrophic enlargement of follicles associated with excessive accumulation of colloid (Fig. 8).



**Figure 8.** Follicle diameter,  $\mu\text{m}$

Compared to the control group, follicular area in the central region decreased by 1.22 times in Mg deficiency, 1.34 times in Fe deficiency, 1.16 times in Se deficiency, 1.13 times in Zn deficiency, and 1.52 times in combined deficiency; in the peripheral region, it increased by 1.27, 1.41, 1.19, 1.15, and 1.59 times, respectively. These findings indicate expansion of the follicular apparatus against the background of functional insufficiency (Fig. 9).

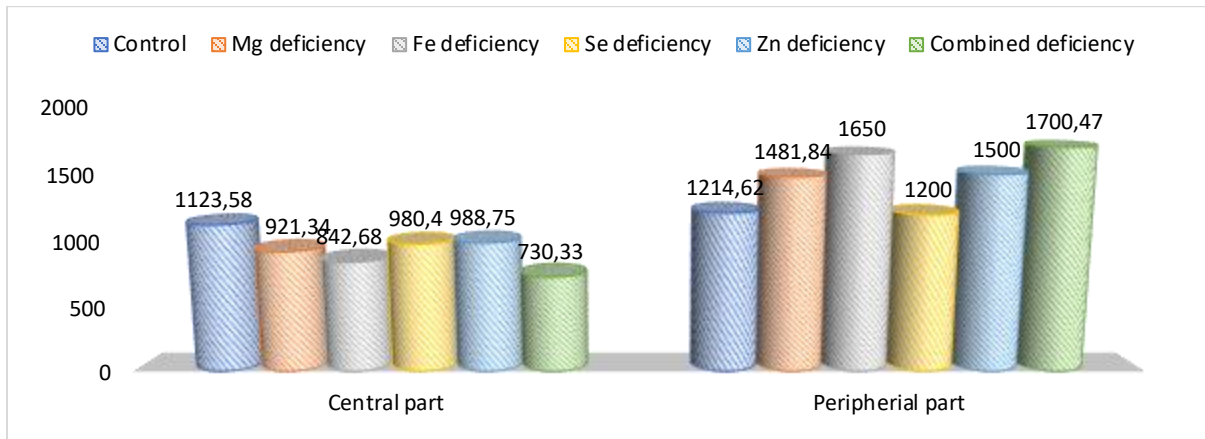


Figure 9. Follicular area,  $\mu\text{m}^2$

Compared to the control group, stromal area in the central region increased by 1.31 times in Mg deficiency, 1.46 times in Fe deficiency, 1.24 times in Se deficiency, 1.19 times in Zn deficiency, and 1.68 times in combined deficiency; in the peripheral region, it increased by 1.28, 1.42, 1.22, 1.17, and 1.63 times, respectively. These changes indicate predominance of the stromal component and intensification of fibrotic processes (Fig. 10).

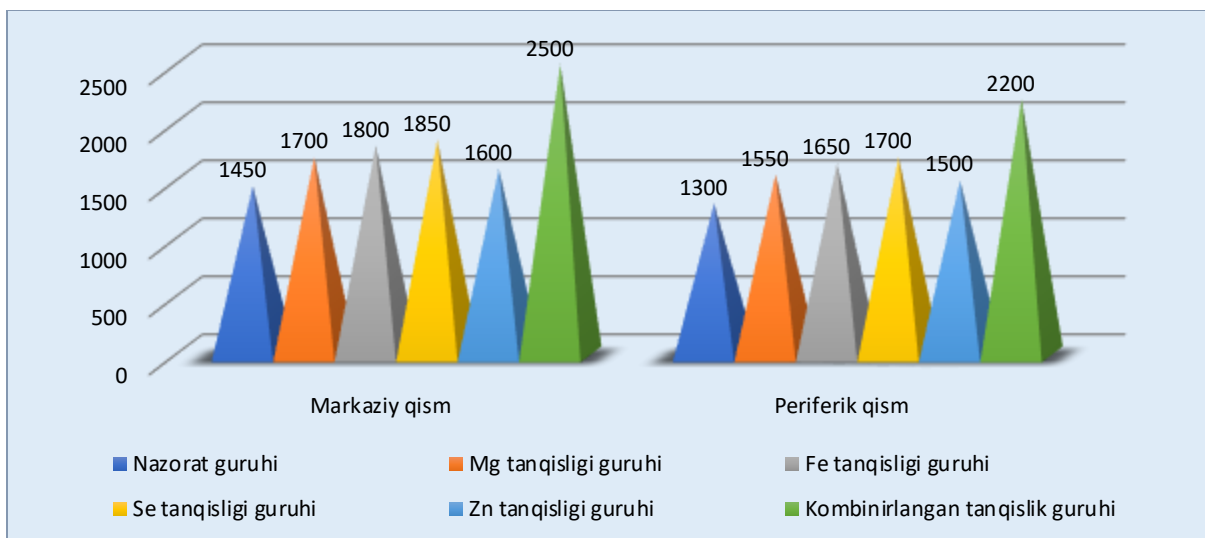
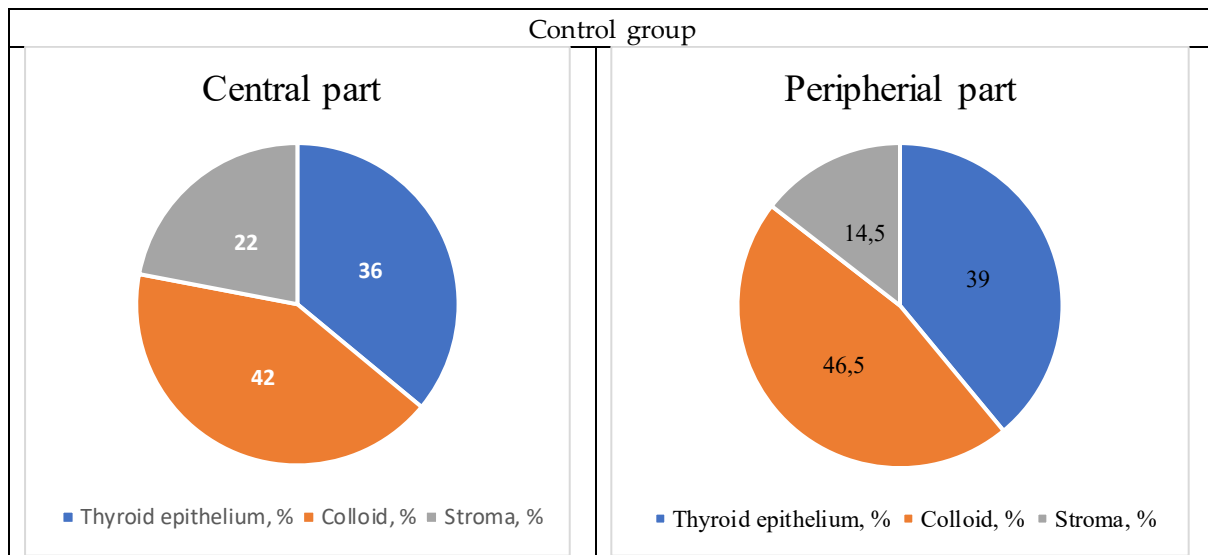
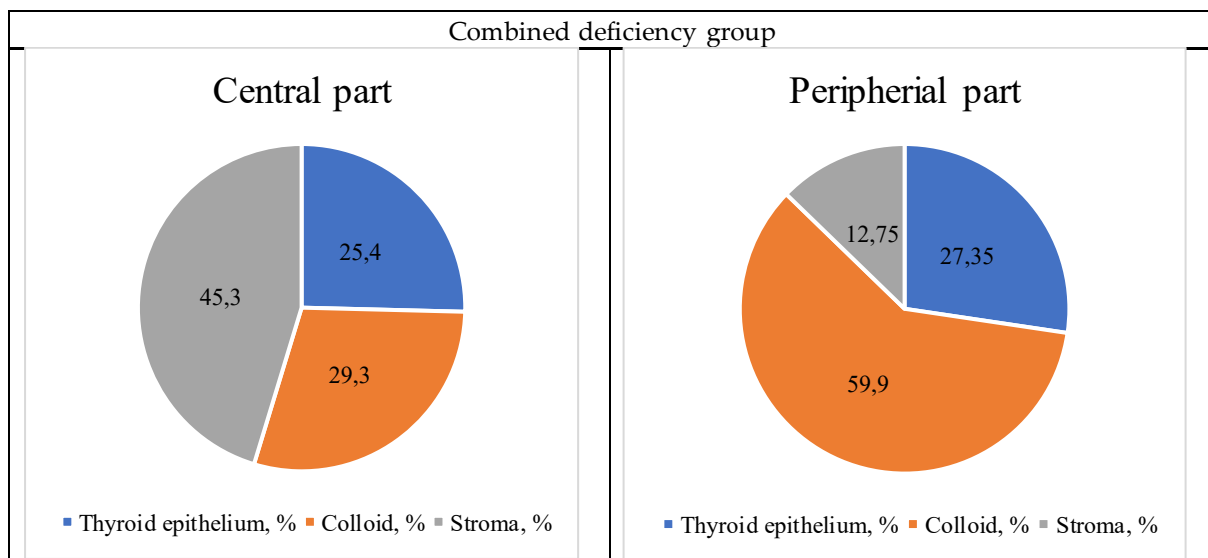


Figure 10. Stromal area,  $\mu\text{m}^2$

Compared to the control group, in the combined deficiency group the proportion of thyroid epithelium in the central region decreased by 1.42 times, and the colloid fraction decreased by 1.43 times, while the stromal fraction increased by 2.06 times; in the peripheral region, the epithelial fraction decreased by 1.43 times and the stromal fraction by 1.14 times, whereas the colloid fraction increased by 1.29 times. These findings indicate predominance of stromal elements in the central region at the expense of parenchymal components (Figs. 11a, b) [15].

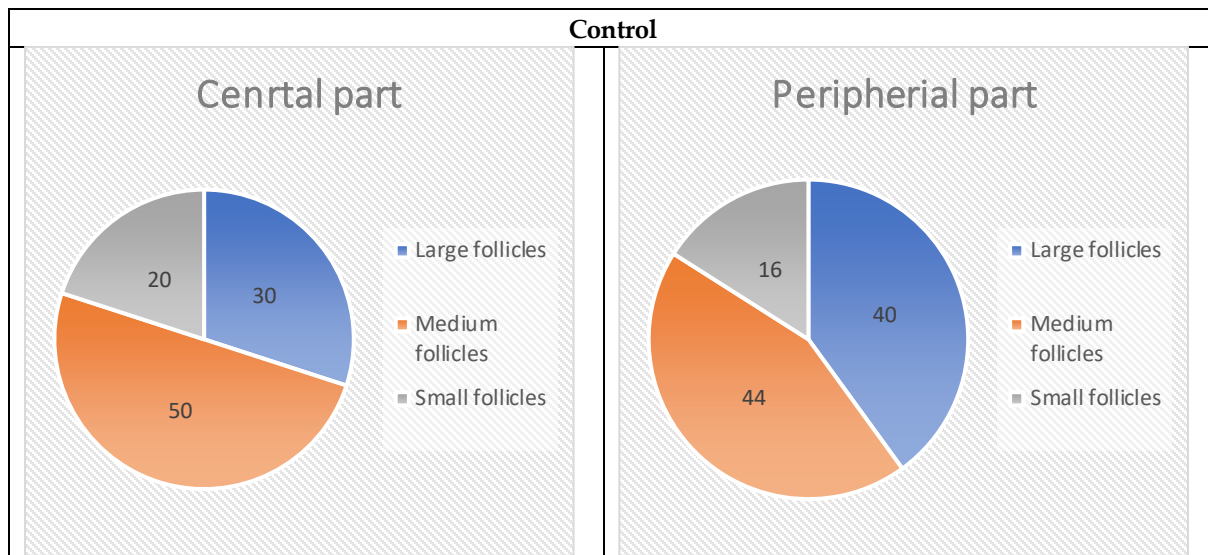


**Figure 11a.** Proportion of thyroid epithelium, colloid, and stroma in the gland tissue, %



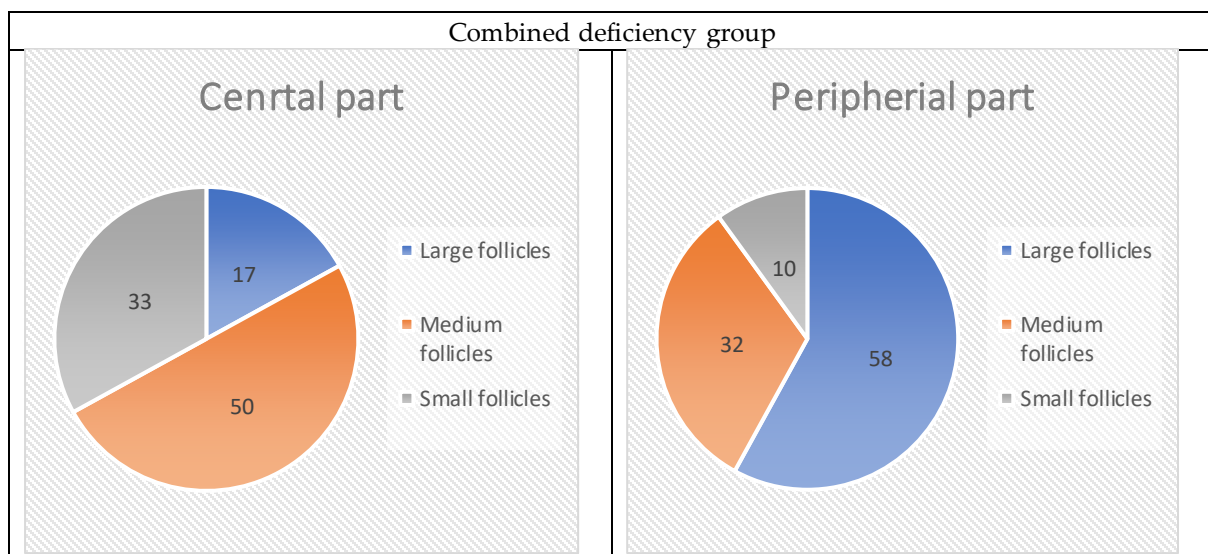
**Figure 11b.** Proportion of thyroid epithelium, colloid, and stroma in the gland tissue, %

Compared to the control group, in the combined deficiency group the proportion of large follicles in the central region decreased by 1.76 times, while the proportion of small follicles increased by 1.65 times, and the proportion of medium follicles remained nearly unchanged; in the peripheral region, the proportion of large follicles increased by 1.45 times, whereas medium and small follicles decreased by 1.38 and 1.60 times, respectively. These changes are characterized by zonal remodeling of the follicular structure (Figs. 12a, b).



**Figure 12a.** Proportion of large, medium, and small follicles in the gland tissue, %

According to the OD index results, in the 3-month control group the relative density and accumulation of colloid in both central and peripheral regions of the thyroid gland were balanced. With increasing age (in the 6-month control group), these parameters remained largely unchanged, indicating structural stability and physiological adaptation of the gland. Under conditions of microelement deficiency, however, directional and quantitatively distinct changes in the colloid OD index were observed.



**Figure 12b.** Proportion of large, medium, and small follicles in the gland tissue, %

In Zn deficiency, the colloid OD index decreased in the central region compared to both 3- and 6-month control groups, while a relative increase was observed in the peripheral region, indicating redistribution of the follicular apparatus and a tendency for colloid accumulation toward the periphery. Under Se deficiency, a further decrease in the colloid OD index was observed in the central region, whereas in the peripheral region it remained close to control values or slightly increased, reflecting remodeling processes and uneven reduction of secretory activity in the gland.

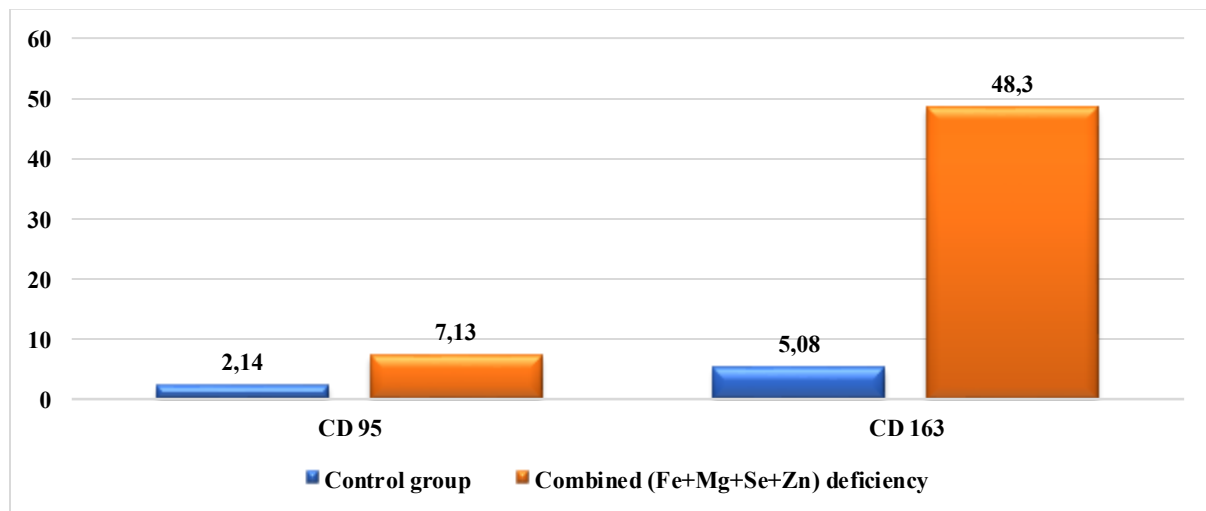
In Mg deficiency, a consistent decrease in the colloid OD index in the central region and a significant increase in the peripheral region were observed, indicating compensatory accumulation of colloid toward the periphery against the background of microcirculatory disturbances. In Fe deficiency,

changes in the colloid OD index were more pronounced, with the lowest values recorded in the central region and a sharp increase in the peripheral region, indicating progression of morpho functional insufficiency of the gland.

The highest and most unbalanced colloid OD index was observed under combined (Fe+Mg+Se+Zn) deficiency, characterized by a sharp decrease of colloid in the central region and maximal accumulation in the peripheral region, reflecting severe structural disruption and functional degradation of the gland.

Overall, comparative analysis of the colloid OD index demonstrated that disturbances in colloid distribution and density in the thyroid gland remained stable in 3- and 6-month control groups, whereas under microelement deficiency they progressively increased in severity in the sequence Zn → Se → Mg → Fe → combined deficiency.

Compared to the control group, in the combined deficiency group CD95 expression increased by 3.33 times, while CD163 expression increased by 9.49 times. A moderate increase in CD95 indicates activation of apoptotic processes, whereas a marked increase in CD163 reflects a shift of macrophages toward the M2 phenotype and predominance of stromal remodeling processes under chronic inflammatory conditions (Fig. 13).



**Figure 13.** CD 95 va CD 163 markerlarining qalqonsimon bez to'qimasida ekspressiya darajasi

According to the conducted histomorphometric analysis, in 6-month-old white outbred rats under conditions of microelement deficiency, morphological and microcirculatory changes in the thyroid gland progressively increased depending on the type of microelement deficiency and their combinations.

In Zn deficiency, the changes were relatively moderate and were mainly manifested by redistribution of the follicular apparatus, predominance of the colloid component, and a decrease in thyroid epithelial height and proportion. In Se deficiency, these processes became more pronounced, accompanied by signs of remodeling, increased stromal area and capsule thickness, and were characterized by more significant morphological alterations compared to Zn deficiency.

Under Mg deficiency, microcirculatory disturbances predominated in the thyroid gland: significant decreases in capillary diameter, capillary density, total capillary cross-sectional area, and relative vascular area indicated progressive impairment of trophic supply and deepening of morphofunctional insufficiency. These changes were more severe than in Zn and Se deficiency but less pronounced than in Fe deficiency and combined deficiency.

## Conclusion

In Fe deficiency, microcirculatory parameters showed even more pronounced reduction, accompanied by marked restructuring of the follicular apparatus, predominance of the colloid component, and significant decrease in thyroid epithelial height and proportion, confirming the development of severe morphofunctional insufficiency of the gland.

The most severe and complex alterations were observed under combined (Fe+Mg+Se+Zn) deficiency, characterized by predominance of small follicles in the central region, maximal increase of the colloid component, sharp reduction of thyroid epithelial height and proportion, pronounced thickening of the stroma and capsule, and the lowest levels of microcirculatory parameters.

Thus, the severity of morphofunctional disorders in the thyroid gland progressively increased in the sequence Zn deficiency → Se deficiency → Mg deficiency → Fe deficiency → combined microelement deficiency, reaching its highest level under combined deficiency conditions.

## REFERENCES

- [1] L. E. Braverman and D. S. Cooper, *Werner & Ingbar's The Thyroid: A Fundamental and Clinical Text*, 10th ed. Philadelphia, PA: Lippincott Williams & Wilkins, 2013.
- [2] A. P. Weetman, "Autoimmune thyroid disease," *New England Journal of Medicine*, vol. 343, no. 17, pp. 1236–1248, 2000.
- [3] R. S. Bahn and H. B. Burch, "Hyperthyroidism and other causes of thyrotoxicosis," *The Lancet*, vol. 362, no. 9382, pp. 459–468, 2003.
- [4] M. B. Zimmermann, "Iodine deficiency," *Endocrine Reviews*, vol. 30, no. 4, pp. 376–408, 2009.
- [5] WHO, *Assessment of Iodine Deficiency Disorders and Monitoring Their Elimination*, 3rd ed. Geneva: World Health Organization, 2007.
- [6] F. Delange, "The disorders induced by iodine deficiency," *Thyroid*, vol. 4, no. 1, pp. 107–128, 1994.
- [7] B. Hetzel, *The Story of Iodine Deficiency: An International Challenge in Nutrition*. Oxford: Oxford University Press, 1989.
- [8] E. A. Miles, "Trace elements and thyroid function," *Nutrition Reviews*, vol. 58, no. 10, pp. 295–302, 2000.
- [9] J. Köhrle, "Selenium and the thyroid," *Current Opinion in Endocrinology, Diabetes and Obesity*, vol. 22, no. 5, pp. 392–401, 2015.
- [10] M. Vanderpump, "The epidemiology of thyroid disease," *British Medical Bulletin*, vol. 99, no. 1, pp. 39–51, 2011.
- [11] A. B. Smith et al., "Microcirculatory changes in thyroid pathology," *Journal of Endocrinology*, vol. 210, no. 2, pp. 123–130, 2011.
- [12] G. Williams, "Morphological changes in thyroid tissue under micronutrient deficiency," *Histopathology*, vol. 45, no. 3, pp. 210–218, 2004.
- [13] R. De Groot et al., *Endocrinology*, 7th ed. Philadelphia, PA: Elsevier, 2016.
- [14] S. C. Werner, "Thyroid microstructure and vascularization," *Endocrine Pathology*, vol. 18, no. 2, pp. 67–75, 2007.
- [15] I. Duntas and J. Benavente, "The role of micronutrients in thyroid function and disorders," *Endocrine*, vol. 55, no. 3, pp. 567–575, 2017.