

The Origin of Open-Angle Glaucoma and Modern Clinical Diagnostic Methods!

Abdullaeva Dilorom Rustamovna

Assistant, Department of Ophthalmology, Samarkand State Medical University

Received: 2024, 15, Dec

Accepted: 2024, 21, Jan

Published: 2025, 22, Feb

Copyright © 2025 by author(s) and BioScience Academic Publishing. This work is licensed under the Creative Commons Attribution International License (CC BY 4.0).



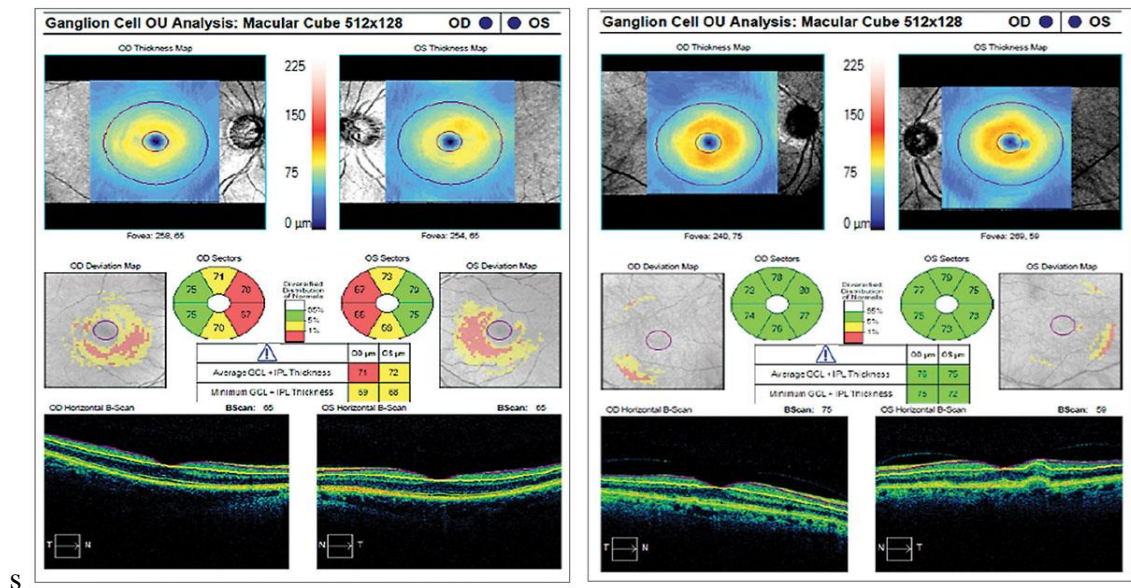
Open Access

<http://creativecommons.org/licenses/by/4.0/>

Annotation: Glaucoma is a leading cause of blindness worldwide, characterized by progressive damage to the optic nerve and irreversible loss of retinal neurons. The disease poses significant challenges in both diagnosis and treatment, as its symptoms often remain unnoticed until the later stages. Early detection is crucial for preventing severe vision impairment, yet the asymptomatic nature of glaucoma makes timely diagnosis difficult. While lost neurons cannot be regenerated, appropriate therapeutic interventions can effectively slow disease progression, preserving visual function. This study explores current diagnostic techniques and treatment strategies for glaucoma, emphasizing the importance of early intervention and long-term management in mitigating its impact on vision loss.

Keywords: Glaucoma, Prevalence, Classification, Causes and progression of the disease, Symptoms, Complications, Diagnosis.

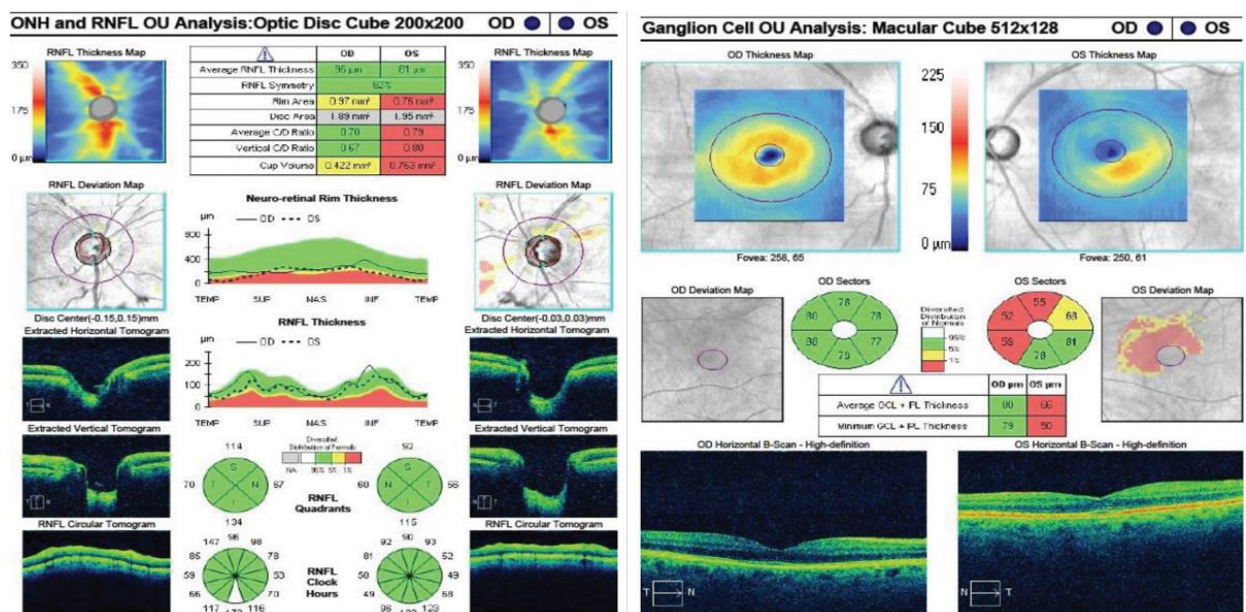
Introduction: The transparent, white outer layer is called the sclera. At the front of the eye, the membrane turns into a transparent convex cornea, which largely controls the refraction of light. The main function of the outer shell is to maintain intraocular pressure and the correct shape of the eye. As we age, the outer shell of all people loses its elasticity and becomes stiffer.[1]



Behind the iris is the ciliary body, which produces intraocular fluid and holds the crystalline lens, a transparent biological lens, capable of changing its curvature, thereby providing a clear image.

The space between the cornea and the iris is the anterior chamber of the eye, and the space between the iris and the lens is the posterior chamber. Both chambers are filled with intraocular fluid (its second name is "aqueous humor"). This fluid is necessary for the refraction of light, and is also saturated with nutrients necessary for the normal functioning of the organ of vision.

The depth of the anterior chamber is approximately 3-3.5 mm, the posterior chamber is significantly narrower. Both cavities communicate with each other through the pupil. Normally, the volume of the eye chambers does not change due to the inflow and outflow of intraocular fluid.[2]



One of the most important structures of the eye is the anterior chamber angle. It is formed where the cornea meets the sclera and the iris meets the ciliary body. It is here that the Schlemm's canal is located, through which moisture flows. This is the drainage system of the eye, the dysfunction of which leads to increased intraocular pressure.[3]

The inner layer (retina) contains visual receptors known as cones and rods. Electrical signals from the receptors are transmitted to the optic nerve, which, through its fibers, enters the cerebral cortex.

The place where the optic nerve exits is called the blind spot - it contains neither rods nor cones.

Under the retina of the eye is the vitreous humor, a transparent, jelly-like substance that maintains the shape and tone of the eye and also participates in the transmission of light rays. In front, the vitreous humor is limited by the lens.

Glaucoma is a general name for a group of eye diseases in which intraocular pressure (IOP) is constantly or periodically increased. As a result, irreversible changes occur in the retina and damage to the optic nerve, which leads to impaired vision and even blindness.[4]

The term "glaucoma" (from the Greek glaukos - "watery blue") was first mentioned in the works of Hippocrates around 400 BC. He called it an eye disease that leads to blindness. As it turned out later, the famous physician did not see the difference between glaucoma and cataracts, so he combined them into one disease.

The disease is named glaucoma because in the later stages, the cornea of the eye may take on a cloudy bluish color.[5]

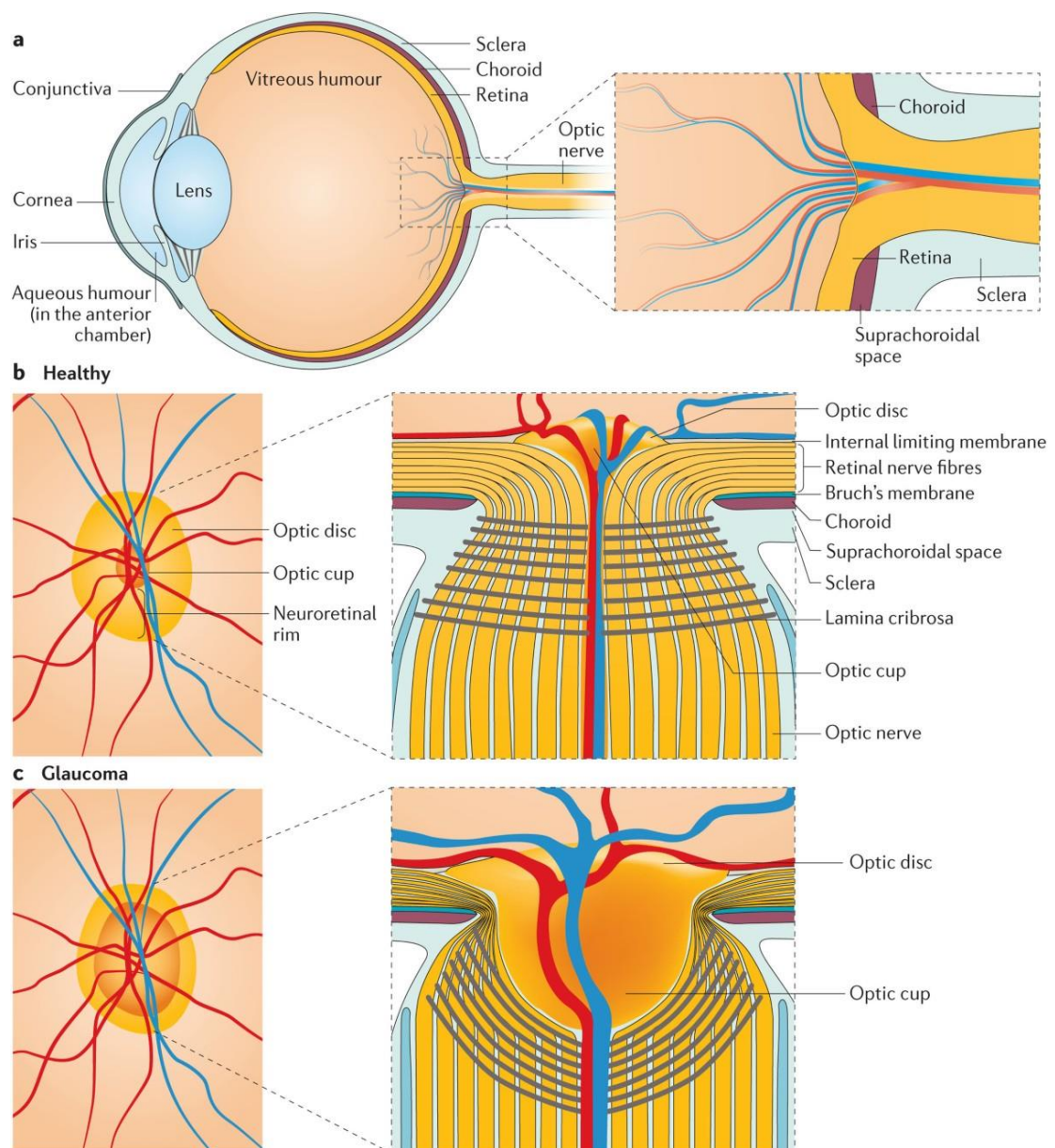
A "cloudy" eye can be a sign of not only glaucoma, but also other diseases that can only be diagnosed by a doctor.

In the International Classification of Diseases, 10th revision (ICD-10), glaucoma is designated by the code H40. Separate codes are allocated for different variants of the disease:

- a. H40.0 - suspected glaucoma;
- b. H40.1 - Primary open-angle glaucoma;
- c. H40.2 - Primary angle-closure glaucoma;
- d. H40.3 - secondary glaucoma after trauma;
- e. H40.4 - Glaucoma secondary to inflammatory eye disease;
- f. H40.5 - glaucoma secondary to other eye diseases;
- g. H40.6 - glaucoma secondary to drug use;
- h. H40.8 - Other glaucoma;
- i. H40.9 - glaucoma, unspecified;
- j. Q15.0 - Congenital glaucoma.

Glaucoma is a serious disease and the main cause of irreversible blindness. In most patients, pathological changes affect both eyes. Every second person with glaucoma does not even suspect that they have the disease.[6]

According to the World Health Organization (WHO), about 600,000 new cases of blindness due to glaucoma are recorded each year, and the total number of people suffering from this disease in the world has already exceeded 100 million.



Nature Reviews | Disease Primers

Every minute, one adult in the world becomes blind from glaucoma, and every 10 minutes, one child becomes blind.[7]

Research methods and materials: Glaucoma can be primary (occurs spontaneously and affects only intraocular structures) and secondary (a consequence of injuries and other diseases).

The disease is also classified by origin, course, level of intraocular pressure, and condition of the optic nerve.

Open-angle glaucoma is glaucoma that develops due to problems with the drainage system, meaning the angle of the anterior chamber of the eye is open. If the angle is blocked by something, it is a closed-angle form. There is also a mixed type of glaucoma.

One of the most important indicators in glaucoma is the level of intraocular pressure (IOP). The measurement of IOP is called tonometry. Depending on the measurement method, a distinction is made between tonometric (contact method) and true (non-contact method) intraocular pressure.[7]

Intraocular pressure level

- a. IOP level
- b. Tonometric (Pt),

- c. mmHg Art.
- d. True (Po),
- e. mmHg Art.

Simple

- a. < 25
- b. < 21

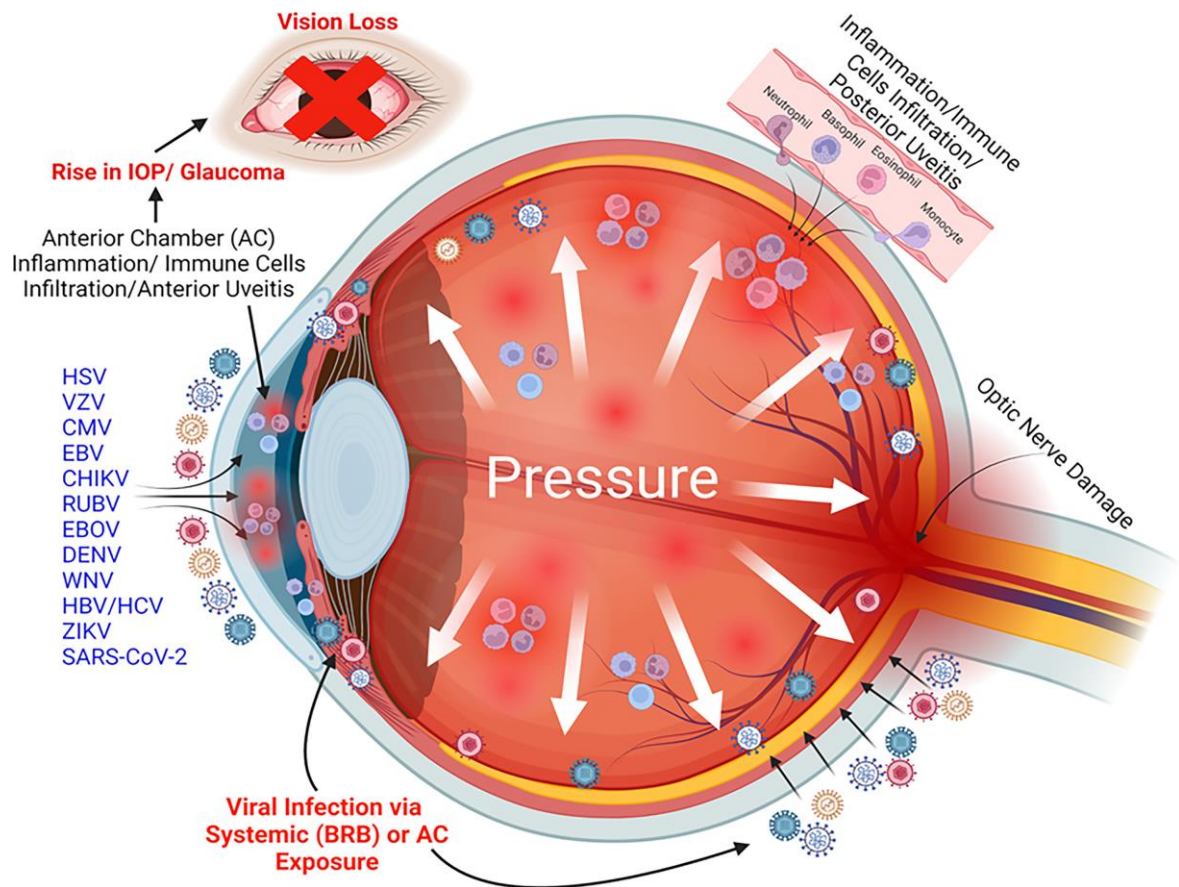
Moderately elevated

- a. 26–32
- b. 21–26

High

- a. > 32
- b. > 26

stabilized - the patient is observed for 6 months or more, during which time the vision and condition of the optic nerve do not deteriorate;



Unstable - the doctor detects deterioration during subsequent examinations.

Stages of glaucoma depending on the condition of the optic nerve :

- a. elementary;
- b. developed;
- c. advanced stage;
- d. terminal.

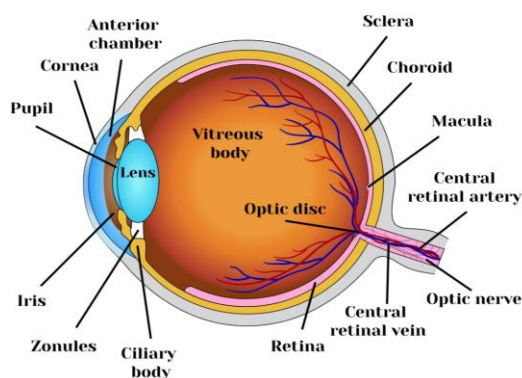
The condition of the optic nerve can only be assessed through an ophthalmological examination. The division of the development of glaucoma into stages is arbitrary.[8]

By time of onset of glaucoma:

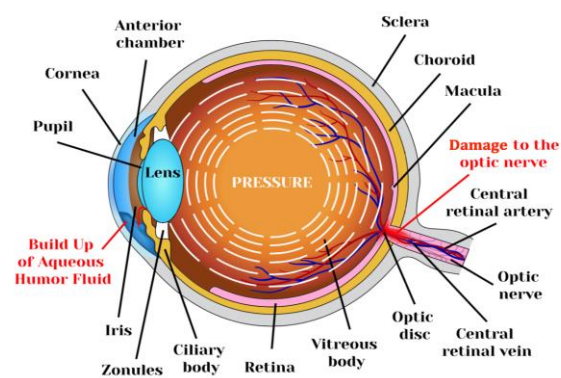
- congenital: in children under 3 years of age;
- infantile: from 3 to 10 years old;
- Minors: from 11 to 35 years old;
- Glaucoma in adults over 35 years of age.

When making a diagnosis, doctors take into account the type of glaucoma, its stage, the level of intraocular pressure, and changes in vision. An example of a diagnosis: primary open-angle, advanced stage with moderately elevated pressure, stabilized glaucoma.[9]

Normal vision



Glaucoma



Results: In a healthy eye, aqueous humor circulates easily and unhindered. If the production or outflow of this fluid is impaired, glaucoma develops: when its large amount accumulates, intraocular pressure (IOP) increases.

Normal IOP is 18-24 mm Hg. Art. If intraocular pressure is high, it is called ocular hypertension. Doctors may suspect glaucoma in a person who has no symptoms of the disease but has elevated IOP.

Increased intraocular pressure leads to irreversible damage to the optic nerve and blindness.

The causes of ocular hypertension and glaucoma are very diverse, many of which are still controversial in scientific circles.[10]

Primary glaucoma

The main cause of primary glaucoma is tissue dystrophy due to a metabolic defect at the cellular level, which leads to impaired or loss of vision. Translated from Greek, dystrophy means "disorder of tissue nutrition."

There are two main forms of primary glaucoma: open-angle and closed-angle. The disease is most often diagnosed in people over the age of 40.[11]

Approximately 90 percent of all glaucoma cases develop primary open-angle glaucoma.

Primary open-angle glaucoma (POAG) occurs when the outflow of aqueous humor from the angle of the anterior chamber of the eye is impaired, meaning that changes affect the drainage system of the eye.[12]

The process develops over a long period of time and is not noticeable to the patient. As a result, excessive pressure damages the optic nerve: first, peripheral vision is lost, and then central vision.

Due to the insidious nature of the disease, primary open-angle glaucoma is sometimes called the silent thief of vision.

In primary open-angle glaucoma, there is an open angle in the anterior chamber of the eye and a violation of the outflow of fluid in the drainage system.[13]

The main risk factors for primary open-angle glaucoma are:

- a. over 40 years of age;
- b. heredity - this disease is detected 4-9 times more often in relatives of patients with glaucoma;
- c. symptomatic intraocular hypertension - with an increase in intraocular pressure by 1 mm Hg. Art. the risk of glaucoma increases by 10%;
- d. pseudoexfoliation syndrome - protein deposits in the anterior structures of the eye due to metabolic disorders in connective tissues, increases the risk of POAG by 9-11 times;
- e. thinning of the central zone of the cornea. Normal values for its thickness are 473-597 μm , and for every 40 μm of thinning, the risk of POAG increases by 30-41%;
- f. Myopia - moderate (from 3.25 diopters) and high degrees of the disease (6 or more diopters) are important for POAG.[13]
- g. Primary angle-closure glaucoma (PACG) occurs when the natural outflow of aqueous humor is blocked due to the closure of the anterior chamber angle. The process progresses very quickly: if you do not consult a doctor as soon as possible, you can lose your vision.[14]



Risk factors for primary angle-closure glaucoma:

- a. congenital eye defects - narrow anterior chamber, abnormal size of the lens, cornea, location of the ciliary body;
- b. acquired conditions - age-related changes in the size of the lens and flattening of the iris, accumulation of fluid in the posterior part of the vitreous body;

- c. age - the risk increases in people over 60 years of age, as over the years there is a gradual "shallowing" of the anterior chamber and narrowing of the angles;
- d. female gender - women have physiologically narrower anterior chamber angles, so the risk of developing PACG is 4 times higher than in men;
- e. heredity - the likelihood of developing this form of glaucoma is much higher due to the fact that close relatives inherit anatomical features of the eye structures.[15]

Secondary glaucoma

Secondary glaucoma is caused by mechanical damage to the eye, as well as diseases that affect the outflow of intraocular fluid and lead to increased intraocular pressure. The condition is not age-related.

The frequency of secondary glaucoma varies depending on the cause:

- a. open and closed eye injuries - in 35-64% of cases;
- b. inflammation of the choroid - 12-36%;
- c. neovascularization of the anterior segment of the eye (a condition in which blood vessels grow into the anterior chamber and the angle of the iris) - 6-16%;
- d. burns - 2-16%.
- e. Secondary glaucoma can also be caused by lens pathologies, intraocular tumors, and inflammatory eye diseases. How and in what way secondary glaucoma progresses depends on the underlying disease or condition.

Congenital glaucoma

Congenital glaucoma is usually associated with a violation of the intrauterine development of the eye's drainage system or the anterior chamber angle. Most often, the pathology manifests itself in the first 3 years of a child's life.

According to various reports, between 2 and 15 percent of blind children have lost their vision due to congenital glaucoma. In 75% of cases, the changes affect both eyes.

Possible causes of congenital glaucoma in children:

- a. intrauterine infections - rubella, measles, mumps, toxoplasmosis, etc.;
- b. poisoning of a pregnant woman with heavy metal salts;
- c. ionizing radiation to which a woman was exposed during pregnancy;
- d. metabolic disorders (thyrotoxicosis) in the expectant mother.
- e. Heredity and premature birth of a child - up to 35 weeks - are of no small importance.

The eye of a three-year-old boy with congenital glaucoma caused by intrauterine infection with the rubella virus

In children with congenital glaucoma, the outflow of aqueous humor is impaired and intraocular pressure increases. This leads to stretching of the elastic membranes of the child's eyeball, changes in blood circulation, and damage to the optic nerve.

Symptoms of different types of glaucoma

The symptoms of glaucoma depend on the type and stage of the disease. The manifestations of open-angle and closed-angle forms differ significantly.

Open-angle glaucoma symptoms

Primary open-angle glaucoma is the most common type of glaucoma. The damage to the eye

occurs slowly and painlessly, so many people are unaware they have the disease. Often, the disease has caused irreversible vision damage long before it is diagnosed.

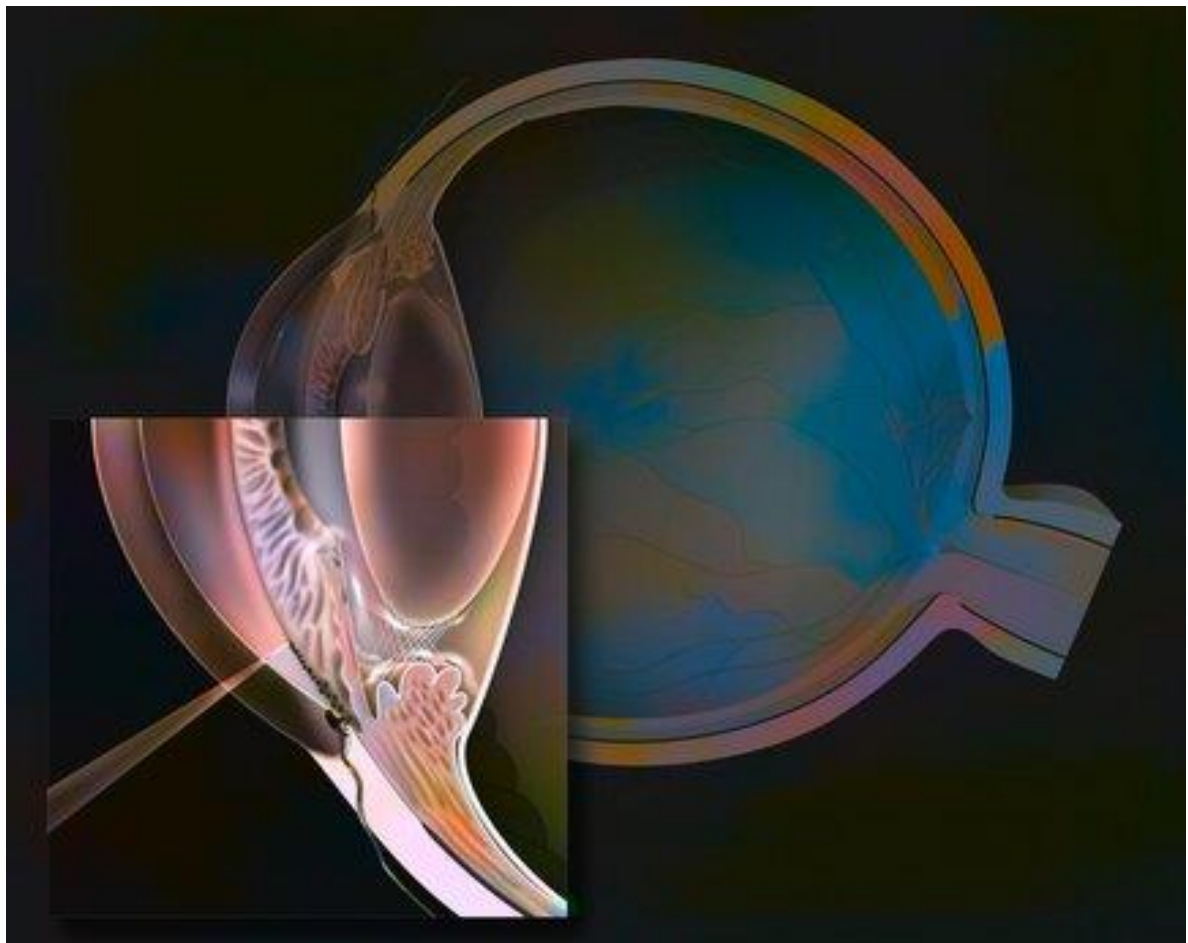
A typical symptom of primary open-angle glaucoma (POAG) is the gradual loss of peripheral (side) vision. Patients describe this condition as the appearance of "blind spots" in the periphery. This is followed by a loss of central vision - it is difficult for a person to see objects that are directly in front of them. The process can progress to complete blindness.

Visual impairment in open-angle glaucoma depending on the stage of the disease

- a. Patients with glaucoma have atypical complaints:
- b. temporary blurred vision;
- c. rainbow circles around light sources;
- d. flashing mosquitoes;
- e. headache;
- f. eye pain;
- g. lacrimation.

Examination of patients with POAG reveals periodic or persistent elevations in intraocular pressure. The difference between the two eyes may be more than 2-3 mmHg. Art., and the range of fluctuations during the day may exceed 5 mm Hg. Art.

On average, it can take 1 to 5 years from the onset of the disease to its first symptoms. In some cases, glaucoma can go through all stages from initial to final within 5 years.



Symptoms of angle-closure glaucoma

Primary angle-closure glaucoma (PACG) is less common and the "silent thief of sight" - manifests

itself much more clearly than the open-angle form of the disease.

Often, angle-closure glaucoma is characterized by attacks that occur due to a sudden blockage of the angle of the anterior chamber and a violation of the outflow of intraocular fluid. Between attacks, patients do not feel any discomfort. And only when the process becomes chronic, do patients with POAG develop complaints similar to those of patients with POAG.

Symptoms of an attack of closed-angle glaucoma:

- a. sudden and very severe pain in the eyes;
- b. severe headache (localized in the area of the superciliary arches);
- c. blurred vision;
- d. vomiting and/or nausea;
- e. halos or colored rings that appear around light sources;
- f. redness of the eyes;
- g. excessive lacrimation;
- h. Pupil dilation - asymmetrical in both eyes.

Although the disease is bilateral, an acute attack rarely develops in both eyes simultaneously.

External signs of an acute attack of glaucoma:

- a. loss of corneal transparency - due to swelling of the cornea and clouding of the aqueous humor;
- b. asymmetry, pupil dilation and lack of response to light;
- c. gray-green color of the pupil - when the lens swells, it loses its transparency and becomes clogged in the pupil area;
- d. sharp thickening of the eye - a significant increase in tone when pressing on the eye;
- e. flattening of the iris pattern due to swelling;
- f. narrowing of the space between the iris and the cornea;
- g. redness of the eye - as a result of constriction of blood vessels and impaired blood flow.
- h. In closed-angle glaucoma, vision loss can occur within hours of the onset of the disease.
- i. To prevent damage to the optic nerve, you should seek medical attention immediately - doctors will immediately lower the eye pressure.
- j. Acute eye pain can be caused by an acute attack of glaucoma - without urgent help, a person can lose their vision.

In a patient with closed-angle glaucoma, various factors can trigger an acute attack:

- a. stress,
- b. excessive excitement,
- c. working for long periods of time with your head bowed,
- d. large amounts of drunk liquid,
- e. hypothermia,
- f. medical dilation of the pupil to treat or diagnose eye disease.

If the angle of the anterior chamber of the eye does not close completely, the patient develops a subacute attack of glaucoma. Its manifestations are not as pronounced as in an acute attack:

- a. mild pain in the eye,

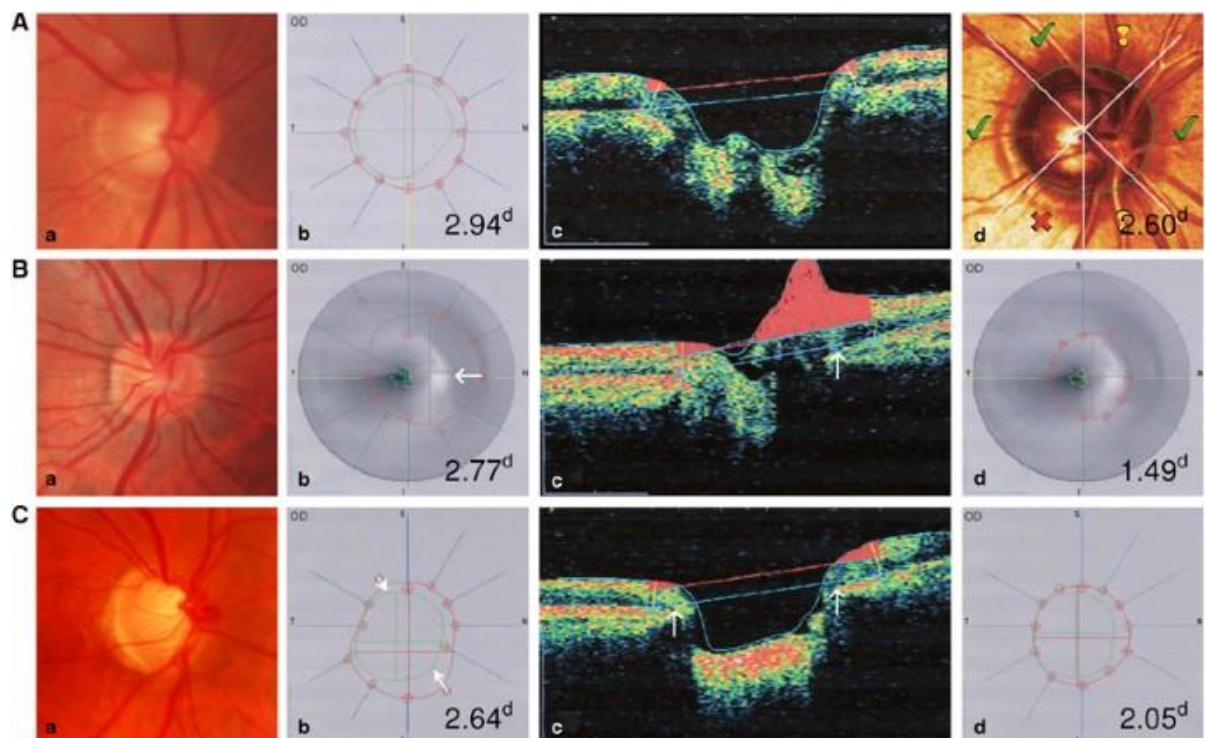
- b. rainbow circles facing the light,
- c. blurred vision,
- d. mild corneal edema,
- e. moderate pupil dilation.

Even minor manifestations of glaucoma cannot be ignored - with each attack, the optic nerve becomes more and more damaged, which threatens complete loss of vision.

Long-term glaucomatous processes - impaired fluid outflow and increased intraocular pressure - lead to serious consequences.

Glaucoma optic neuropathy is damage to the optic nerve due to compression and circulatory problems. This initially leads to partial loss of vision and then blindness.

Terminal painful glaucoma is a condition in which the affected eye experiences constant pain that occurs in the final stages of the disease. Painkillers are ineffective, and the only way to alleviate the condition is to lower the intraocular pressure, but even this therapy only provides temporary relief.



Surgical methods for painful glaucoma are also ineffective and often cause postoperative complications. A radical method to relieve a patient with terminal glaucoma from severe pain is to remove the eyeball.

Conclusion: It is important to detect glaucoma before vision problems occur. A person who develops this pathology does not experience discomfort for a long time and does not seek medical attention, so an ophthalmologist can detect the insidious disease, for example, during a medical examination.

Laboratory tests are not prescribed to diagnose glaucoma, instrumental diagnostics are performed using various methods;

Tonometry is a measurement of intraocular pressure. When analyzing the data, absolute IOP values, its daily fluctuations, the difference in tone between the two eyes, and the characteristics of fluctuations when changing body position from horizontal to vertical are taken into account. If an excess of the norm is detected, monitoring is carried out for several days.

List of used literature:

1. N. Veeraraghavan, «Adult Eye Conditions: Primary Open-Angle Glaucoma and Cataract», *FP Essent.*, т. 519, сс. 19–23, 2022.
2. A. Kastner и A. J. King, «Advanced glaucoma at diagnosis: current perspectives», *Eye Lond.*, т. 34, вып. 1, сс. 116–128, 2020.
3. Liu K. ., He, W. ., Zhao, J. ., Zeng, Y. и H. Cheng, «Association of WDR36 polymorphisms with primary open angle glaucoma: A systematic review and meta-analysis», *Med. Baltim.*, т. 96, вып. 26, с. e7291, 2017.
4. D. L. Budenz *и др.*, «CDKN2B-AS1 genotype-glaucoma feature correlations in primary open-angle glaucoma patients from the United States», *Am. J. Ophthalmol.*, т. 155, вып. 2, сс. 342–353.e5, 2013.
5. G. Thorleifsson *и др.*, «Common variants near CAV1 and CAV2 are associated with primary open-angle glaucoma», *Nat. Genet.*, т. 42, вып. 10, сс. 906–910, 2010.
6. T. Borrás, «Gene expression in the trabecular meshwork and the influence of intraocular pressure», *Prog. Retin. Eye Res.*, т. 22, вып. 4, сс. 435–463, 2003.
7. K. P. Burdon *и др.*, «Genome-wide association study identifies susceptibility loci for open angle glaucoma at TMCO1 and CDKN2B-AS1», *Nat. Genet.*, т. 43, вып. 6, сс. 574–578, 2011.
8. D. Gupta и P. P. Chen, «Glaucoma», *Am. Fam. Physician*, т. 93, вып. 8, сс. 668–674, 2016.
9. S. Monemi *и др.*, «Identification of a novel adult-onset primary open-angle glaucoma (POAG) gene on 5q22.1», *Hum. Mol. Genet.*, т. 14, вып. 6, сс. 725–733, 2005.
10. H. F. Nunes *и др.*, «Investigation of CAV1/CAV2 rs4236601 and CDKN2B-AS1 rs2157719 in primary open-angle glaucoma patients from Brazil», *Ophthalmic Genet.*, т. 39, вып. 2, сс. 194–199, 2018.
11. D. Y. L. Leung и C. C. Tham, «Normal-tension glaucoma: Current concepts and approaches—A review», *Clin. Experiment. Ophthalmol.*, т. 50, вып. 2, сс. 247–259, 2022.
12. M. S. Shim *и др.*, «Optineurin E50K triggers BDNF deficiency-mediated mitochondrial dysfunction in retinal photoreceptor cell line», *Biochem. Biophys. Res. Commun.*, т. 503, вып. 4, сс. 2690–2697, 2018.
13. Parajuli S. ., Shrestha, P. ., Sharma, S. и J. K. Shrestha, «Prevalence of Ocular Hypertension in Patients Above 40 Years of Age», *Nepal J. Ophthalmol.*, т. 14, вып. 27, сс. 140–143, 2022.
14. Weinreb R. N. ., Aung, T. и F. A. Medeiros, «The pathophysiology and treatment of glaucoma: a review», *JAMA*, т. 311, вып. 18, сс. 1901–1911, 2014.
15. M. O. Gordon и M. A. Kass, «What We Have Learned From the Ocular Hypertension Treatment Study», *Am. J. Ophthalmol.*, т. 189, сс. xxiv–xxvii, 2018.