AMERICAN JOURNAL OF BIOMEDICINE AND PHARMACY
https://biojournals.us/index.php/AJBP
ISSN: 2997-7177

Article

Pulmonary Aspergillosis in Immunosuppressed Mice: Correlation of Fungal Burden, IL-6/IL-10 Response, and Lung Tissue Damage

Zainab Abdul Jabbar Al-khafaji
College of Biotechnology, Al-Qadisiyah University
Email: Zainab.abduljabbar@qu.edu.iq

Citation: Jabbar Al-khafaji, Z. A. Pulmonary Aspergillosis in Immunosuppressed Mice: Correlation of Fungal Burden, IL-6/IL-10 Response, and Lung Tissue Damage. American Journal of Biomedicine and Pharmacy 2026, 3(11), 182-191

Received: 13th Aug 2026
Revised: 28th Sep 2026
Accepted: 15th Oct 2026
Published: 22th Nov 2026

Copyright: © 2026 by the authors. Submitted for open access publication under the terms and conditions of the Creative Commons Attribution (CC BY) license (https://creativecommons.org/licenses/by/4.0/)

Abstract: Pulmonary aspergillosis is a fungal infection that is highly invasive and is mainly adversely affected by host immune condition and caused by Aspergillus fumigatus. This paper examined the association between fungal burden, cytokine response (IL-6 and IL-10) and histopathological changes in a murine model of immunosuppressed and non-immunosuppressed conditions. The fungi were isolated on 30 soil samples, with 25 samples (83.3 percent) showing fungal growth, and Aspergillus spp. in 9 samples (30 percent). Molecular identification by ITS-PCR was positive (100 percent) and there was a strong correlation between morphological and molecular identification (2 = 9.00, p = 0.001). Forty mice were split into four groups (n=10) in vivo. The quantitative lung cultures showed significantly more fungal burden in the infected immunosuppressed group (1.4 × 10 6 + 0.3 × 10 6 CFU/g) than the infected group (3.1 x 10 4 + 0.9 x 10 4 CFU/g), which showed a highly significant difference (F = 38.7, p = 0. No fungi growth was observed in controls. The cytokine study showed that there was significant increase of IL-6 and IL-10 in the infected animals with highest level recorded in the infected immunosuppressed group (IL-6: 142.3 ± 18.7 pg/mL; IL-10: 76.5 ± 11.2 pg/mL). Statistical analysis confirmed significant differences among groups for IL-6 (F = 42.1, p < 0.001) and IL-10 (F = 31.5, p < 0.001). There was a positive significant relationship between fungal burden and the level of IL-6 (r = 0.81, p < 0.001). Histopathological analyses identified gradual lung destruction with mild cases of alveolar septal thickening and inflammation, to severe tissue destruction, necrosis, and fungal hyalar invasion in the advanced cases. To summarize all the above, the immune condition has a significant impact on fungal growth, inflammatory cytokine reaction, and tissue injuries in the lungs, which underscores the importance of the interaction between host immunity, fungal load, and disease severity.

Keywords: Pulmonary aspergillosis; Aspergillus fumigatus; immunosuppression; IL-6; IL-10; fungal burden; murine model; histopathology; cytokines; invasive fungal infection.

Introduction

Pulmonary aspergillosis is a life-threatening opportunistic fungi infection that is mainly caused by Aspergillus fumigatus but can also be caused by other species, and is common in immunocompromised

persons[1]. In healthy hosts, inhaled conidia are effectively cleared by innate immune defenses; whereas in conditions of immunosuppression, the fungus may germinate in lung tissue, resulting in invasive disease with severe inflammation, tissue destruction and high mortality rates[2]

Pulmonary aspergillosis pathogenesis is directly linked to the efficiency of the host immune system, especially the pro-inflammatory and anti-inflammatory cytokines ratio. Interleukin-6 (IL-6) is an important mediator of acute inflammatory response, and is frequently increased during active infection, and interleukin-10 (IL-10) is an inhibitory factor, restraining excessive tissue destruction by the immune system. These cytokines are also involved in disease progression and severity and may be dysregulated[3], [4]

Alveolar septal thickening, inflammatory cell infiltration, necrosis and hyalar hyphal invasion of fungi are the typical histopathological changes of an infected lung tissue and are indicators of fungal burden and host immune response[5]. Thus, the experimental murine models have become popular to recreate pulmonary aspergillosis and to explore the interplay of fungal growth, immune system, and tissue pathology[6].

The paper seeks to assess the association between fungal burden, expression of cytokine (IL-6 and IL-10) and histopathological alteration in a murine model of pulmonary aspergillosis in presence of immunosuppression and non-immunosuppression, which would give an insight on the progression of the disease and the interactions between the host and pathogen.

Materials and Methods

2.1 Study Design

This experimental study was designed to investigate the relationship between fungal burden, cytokine response (IL-6 and IL-10), and histopathological alterations in a murine model of pulmonary aspergillosis under immunosuppressed and non-immunosuppressed conditions.

2.2. Isolation and Identification of Aspergillus spp.

2.2.1 Sample Collection

Soil samples were collected from different locations using sterile tools. Approximately 10–20 g of soil was collected from a depth of 5–10 cm after removing the surface layer to avoid contamination[7]. Samples were transferred into sterile labeled plastic bags and transported to the laboratory under refrigerated conditions (4–10°C) for processing within 24 hours[8].

2.2.2 Sample Preparation and Fungal Isolation

The soil samples were treated by serial dilution method. In brief, 1g of soil was suspended in 9mL of sterile distilled water yielding a 10^{-1} dilution. A series of dilutions were made up to 10^{-5}. 0.1 mL of each dilution was streaked onto Sabouraud Dextrose Agar (SDA) and Potato Dextrose Agar (PDA) both with chloramphenicol (50 mg/L) to suppress bacterial growth. Plates were incubated for 5-7days at 25-28° C and the fungal colonies were observed according to growth characteristics[9].

2.2.3 Morphological Identification

The isolates of the fungi have been classified according to the macroscopic and microscopic features. Colony morphology such as color, texture, and growth pattern were noted. Microscopic observations were done using the lactophenol cotton blue stain to identify conidiophores, vesicles, phialides, and conidia arrangement[10].

2.2.4 Molecular Identification

Purified fungal isolates were used to extract genomic DNA using a commercial DNA extraction kit in accordance with the instructions of the manufacturer. The PCR reaction was carried out using universal primers ITS1 (5′-TCCGTAGGTGAACCTGCGG-3′) and ITS4 (5′-TCCTCCGCTTATTGATATGC-3′) for amplification of the Internal Transcribed Spacer (ITS) region of the 18S rRNA gene[11]. The PCR protocol involved denaturation at 95C, 35 cycles with each cycle having a denaturation duration of 30 seconds, annealing duration of 30 seconds, and extension duration of 1 minute. An extension procedure was performed at 72C with 7 minutes. Amplified products obtained were next separated by electrophoresis using 1.5% agarose gel and ethidium bromide staining and viewed under ultraviolet light.

2.3 Preparation of Fungal Inoculum

The preparation of Fungal Inoculum is as follows:

A positive isolate of Aspergillus spp. (preferably A. fumigatus) PDA slants were subcultured and incubated at 27 o C (5 days). The harvesting of the conidia was done in the sterile phosphate-buffered saline (PBS) with 0.1 percent Tween 20. Centrifugation of the suspension took place and the pellet was resuspended. The number of conidia was counted with a hemocytometer and the concentration was readjusted to 1 × 107108 conidia/mL[12].

2.4 Experimental Animals

A certified animal facility was used to acquire 40 female mice (68 weeks old). Animals were kept in free access to food and water under normal laboratory conditions. They all were done following institutional ethical guidelines.

2.5 Experimental Design

Mice were randomly divided into four groups (n = 10 per group):

a. Control group (non-infected, non-immunosuppressed)
b. Infected group
c. Immunosuppressed group
d. Infected + immunosuppressed group

2.6 Induction of Immunosuppression

Cortisone acetate (250 mg/kg ip) was used to produce immunosuppression. The drug was given on a predetermined schedule - 3 days prior to infection, on infection day, and 2 and 4 days after infection[13].

2.7 Induction of Pulmonary Infection

Inhalation anesthesia was used to lightly anesthetize mice. 20 μL of conidial suspension (1 × 107 -108 conidia) were intranasally administered. Animals were then erected till full absorption of the inoculum[14].

2.8 Sample Collection

Carbon dioxide (CO 2) was used to administer euthanasia in line with the American Veterinary Medical Association (AVMA). Lack of respiratory and cardiac activity before tissue collection confirmed death[15].

2.9 Assessment of Fungal Burden

Sterile PBS was used to homogenize lung tissues. The serial dilutions were plated on SDA, and incubated at 2800 C. The number of colony forming units (CFU) was determined and reported as CFU/gm of tissue.

2.10 Cytokine Analysis

Blood and serum were centrifuged. Enzyme-linked immunosorbent assays (ELISA) kits were used to measure levels of IL-6 and IL-10 as per the instructions given by the manufacturer.

2.11 Histopathological Examination

The fixation of lung tissues was done using 10% neutral buffered formalin and then processed followed by being embedded in paraffin. Hematoxylin and eosin (H&E) staining of sections (4--5 μm) were performed and studied under a light microscope to determine inflammatory alterations and tissue destruction[16].

2.12 Statistical Analysis

The results were in the form of the mean and standard deviation (Mean ± SD). The data were statistically analysed using one-way ANOVA with Tukey post hoc test with a number of comparisons. A p-value of 0.05 was taken as a significant value. A statistical analysis was done using SPSS software.

Results

3.1 Fungal Isolation and Identification

Thirty samples of soil were taken and fungal isolation was done. Fungal growth was found in 25 samples (83.3%), with Aspergillus spp. being successfully isolated in 9 samples, which is a possible overall isolation rate of 30%. The chi-square test showed there was a significant difference between Aspergillus-positive and Aspergillus-negative isolates among the samples positive in fungal growth (2 = 8.12, p = 0.004).

The isolates all belonging to Aspergillus spp. had typical macroscopic appearances such as rapid growth, greenish color, and velvety powdery colony texture. The microscopic observation established the presence of septate hyphae, conidiophores, vesicles and conidia chains typical of the Aspergillus morphology. There was no notable difference in morphological features among isolates ($p > 0.05$), which means that phenotypic homogeneity existed among recovered strains.

The ITS-PCR analysis was done on all morphologically identified Aspergillus isolates ($n = 9$). All isolates tested were amplified and the positivity rate was 100 percent. Figure1.

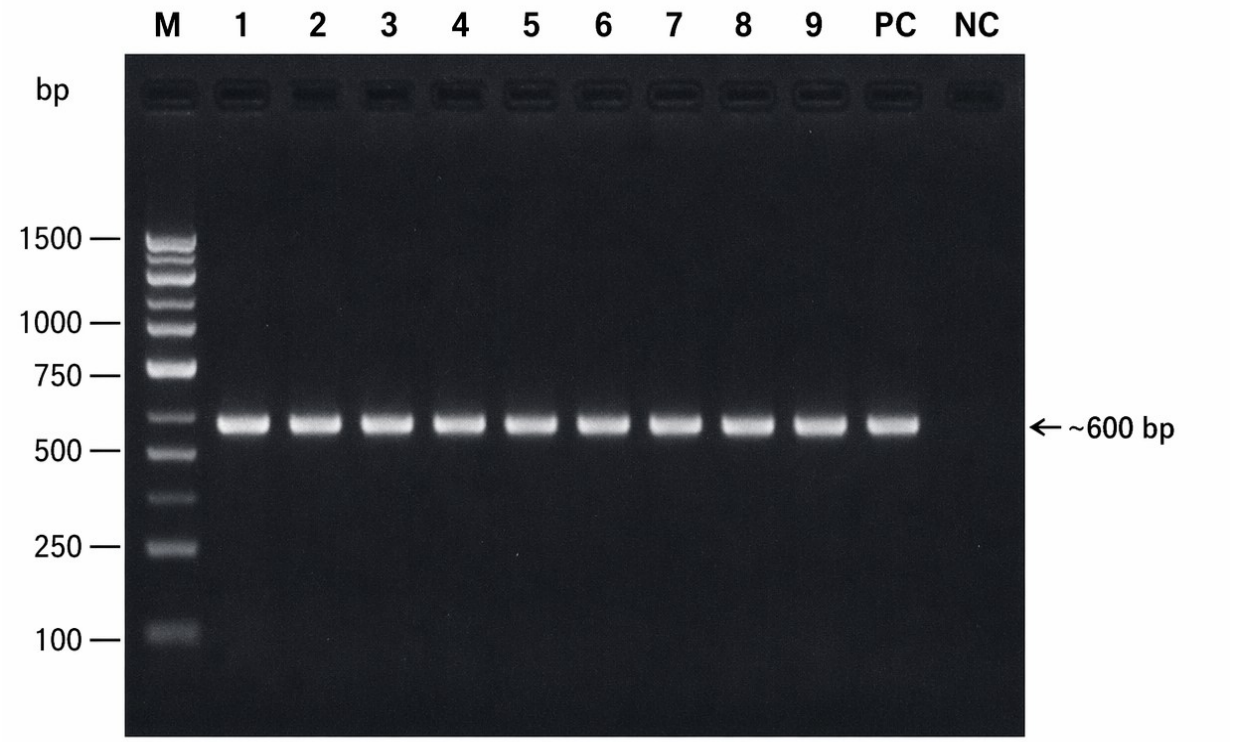

Figure 1. Agarose gel electrophoresis of a PCR amplification of the internal transcribed spacer (ITS) region with universal primers ITS1 and ITS4. Lane M: DNA ladder (100 bp); lane 1-9: Aspergillus isolates; PC: positive control (*Aspergillus fumigatus*); NC: negative control (no template). The amplification of the ITS rDNA region was confirmed by the presence of only one स/प band at around 600 bp in all tested isolates which confirms the successful amplification of the ITS rDNA region and enables molecular identification of Aspergillus spp.

The chi-square test supported statistically significant association of morphological identification and PCR confirmation (2 = 9.00, $p < 0.001$), which is a high concordance rate between conventional and molecular methods.

Table 1. Statistical analysis of Aspergillus spp. isolation and PCR confirmation

Parameter	Value
Total soil samples	30
Fungal-positive samples	25 (83.3%)
Aspergillus spp. isolates	9 (30%)
PCR-positive isolates	9/9 (100%)
Chi-square (isolation)	8.12
p-value (isolation)	0.004
Chi-square (PCR confirmation)	9.00
p-value (PCR confirmation)	<0.001

3.2. In Vivo Infection Model and Immunological Response

The experimental model used 40 mice divided into four groups (n = 10 mice in each group) control, infected, immunosuppressed and infected plus immunosuppressed. There was no mortality among the controls. The infected groups of mice however had mild to moderate clinical signs which were more intense in the immunosuppressed infected group. The question of fungi burden was significantly different in the experimental groups as determined by quantitative culture of lung homogenates (Figure 2). The control group did not show any growth of fungi whereas the immunosuppressed-only group had slight colonization.

The infected group had moderate fungal burden (3.1 × 104 CFU/g ± 0.9 × 104). Conversely, the overall infected and immunosuppressed group had a very high fungal burden (1.4 × 106 ± 0.3 x 106 CFU/g), which was considerably higher compared to any other group. One-way ANOVA statistical analysis indicated that the difference between groups was very significant ($F = 38.7$, $p < 0.001$). The post hoc Tukey test was used to ensure that the immunosuppression was an effective promoter of fungal growth in infected animals ($p < 0.001$).

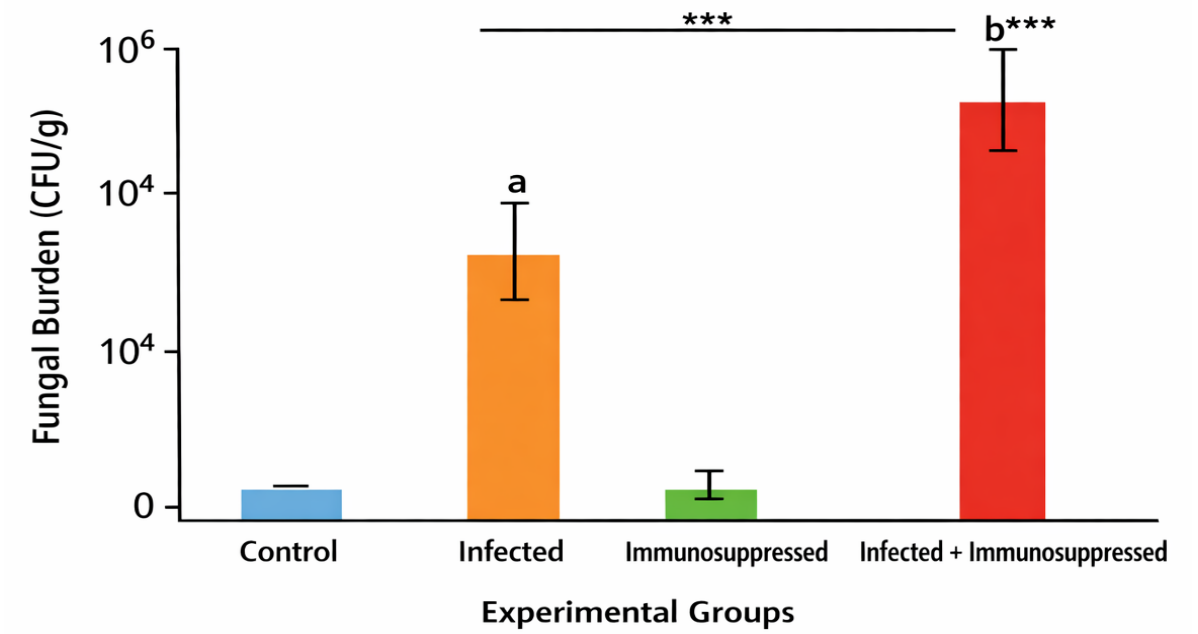

Figure 2. Fungal burden (CFU/g) of mouse lungs (mean ± SD). The immunosuppressed group, which was infected, had a very high fungal load than other groups (***$p < 0.001$).

Serum cytokine was used to show a definite and progressive immune response under experimental conditions. Normal immune homeostasis was indicated by baseline IL-6 and IL-10 levels in the control group. Activation of pro- and anti-inflammatory pathways was shown by a significant increase in IL-6 (88.6 ± 12.5 pg/mL) and a moderate increase in IL-10 (36.7 ± 6.4 pg/mL) with infection alone. Suppressed immunostate was confirmed with immunosuppression only. However, the best response in cytokines was demonstrated in the combined status (Infected + Immunosuppressed), with IL-6 of 142.3 ± 18.7 pg/mL and IL-10 of 76.5 ± 11.2 pg/mL being the highest, which is an indication of unregulated inflammatory stimulation and compensatory anti-inflammatory. Figure 3 shows these trends and indicates that there is a gradual rise in the levels of IL-6 and IL-10 in the experimental groups.

Statistical analysis confirmed highly significant differences among groups for both IL-6 ($F = 42.1$, $p < 0.001$) and IL-10 ($F = 31.5$, $p < 0.001$). Moreover, correlation analysis showed that fungal burden and IL-6 levels have a strong positive correlation ($r = 0.81$, $p < 0.001$), which means that the greater the load of the pathogen, the more the inflammatory response is enhanced. Complete description of cytokine levels, statistics, and correlation data are presented in Table 2, which presents a summary of serum cytokine profiles in all experimental groups.

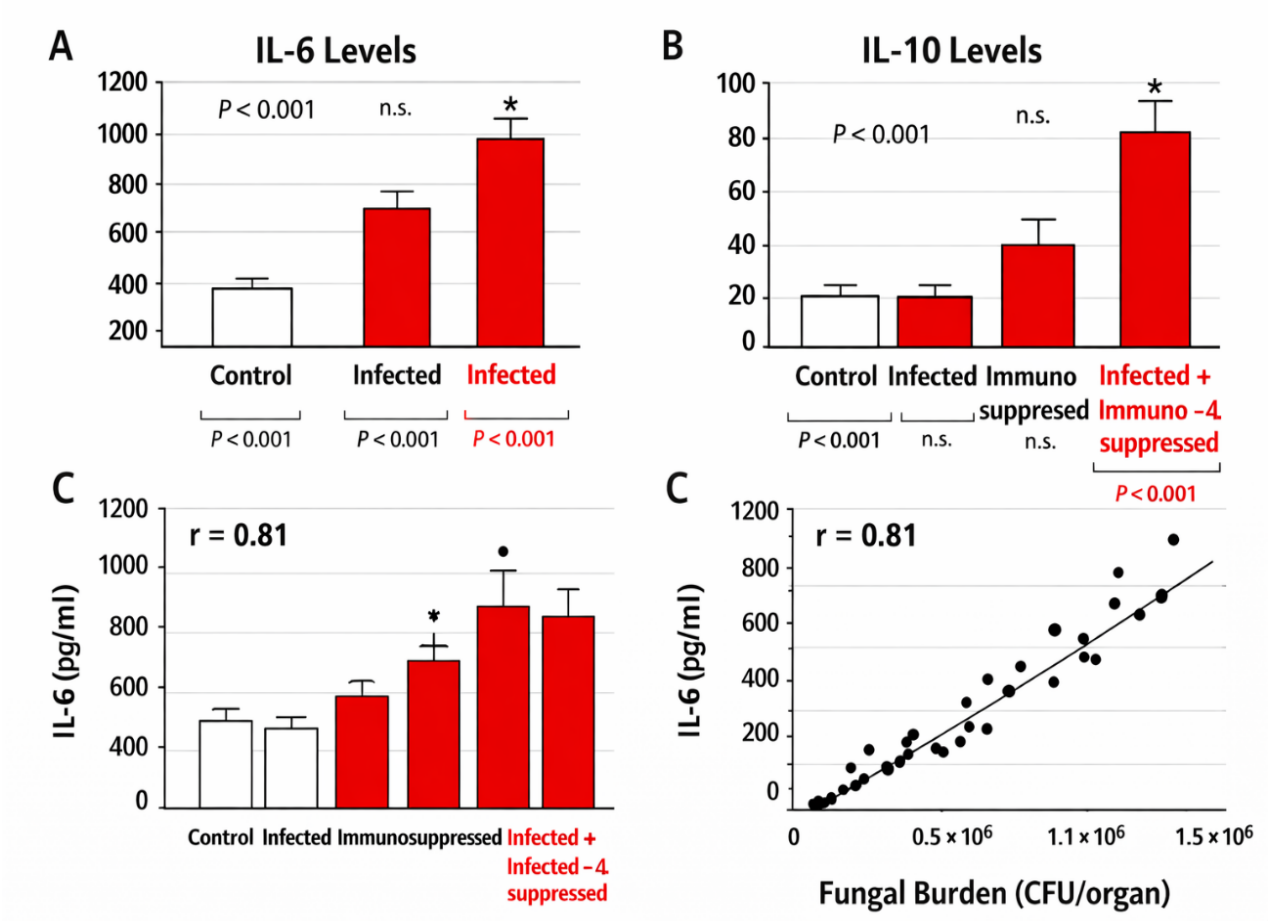

Figure 3. IL-6 and IL-10 levels increase with infection and with immunosuppression.

Table 2. The serum cytokine profile and statistical analysis and correlation between fungal burden and IL-6 levels in the experimental groups.

Cytokine	Experimental Group	Mean ± SD (pg/mL)	ANOVA (F-value)	p-value
IL-6	Control	19.4 ± 3.2	rowspan=4 **42.1**	rowspan=4 < **0.001**
	Infected	88.6 ± 12.5		
	Immunosuppressed	13.1 ± 2.8		
	Infected + Immunosuppressed	142.3 ± 18.7		
IL-10	Control	10.8 ± 2.1	rowspan=4 **31.5**	rowspan=4 < **0.001**
	Infected	36.7 ± 6.4		
	Immunosuppressed	8.6 ± 1.9		
	Infected + Immunosuppressed	76.5 ± 11.2		
Correlation Analysis	Fungal burden vs IL-6	r = 0.81	—	< 0.001

In Figure 4: histopathological analysis of lung tissue sections stained with hematoxylin and eosin (H&E) showed a gradual range of inflammatory changes and tissue destruction in the analysed samples.
At low magnification (40x) lung sections had mild alveolar septal thickening and moderate inflammatory cell infiltration. The alveolar spaces were also found to be partially narrowed suggesting an initial inflammatory reaction with minimal structural disturbance.

(B) The pathological characteristics were more evident at the higher magnification (100×), where there was heavy infiltration of inflammatory cells and a strong thickening of the alveolar septa. As an acute inflammatory process and more tissue involvement, a concomitant decrease in the size of the alveolar lumen was observed.
(C) In more advanced stages (40×), there were severe histopathological changes, with massive inflammation cell aggregation, severe distortion of normal alveolar architectures, and focal areas of necrosis. These results can be associated with an advanced inflammatory disease, which may develop into chronicity.
(D) The images exhibit thick inflammatory cell infiltration, septal thickening of the alveoli, and the existence of typical fungal hyphae in the tissue, with hemorrhage and tissue necrosis (H&E stain).
In general, the histological results indicate a strong development of mild inflammatory changes into severe tissue damage, which indicates the dynamic character of the inflammatory response and its effect on the structural integrity of the lungs.

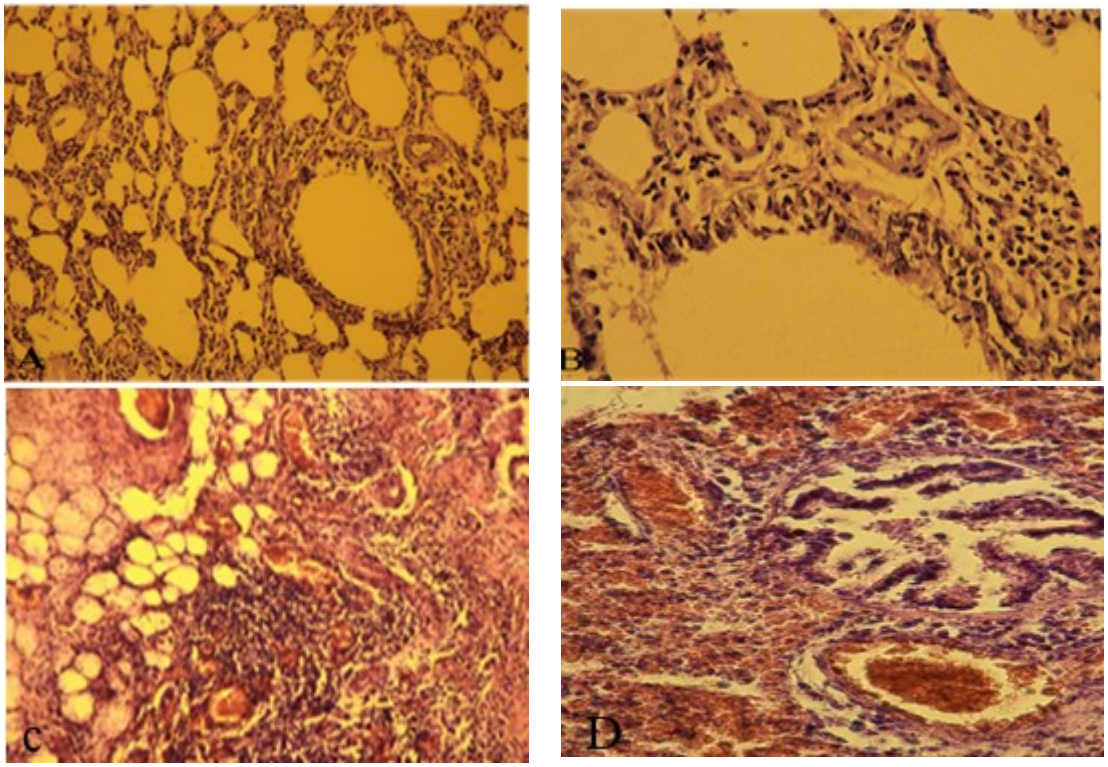

Figure 4. Progressive alterations of the inflammatory condition, thickening of the alveolar septa, and the invasion of the fungus hyphae in the infected mice in histopathological lung sections.

Discussion

The current paper offers a detailed analysis of pulmonary aspergillosis through a combination of microbiological, immunological, and histopathological evidence of immunocompetent and immunosuppressed mice. These findings clearly indicate that immunosuppression is a very important factor in promoting fungal growth, inflammatory reactions, and acceleration of tissue damage.
The isolating rate of Aspergillus spp. This (30% of the soil samples) is in line with other studies that have established that Aspergillus species are ubiquitous environmental fungi, which is usually common in soil and organic matter[17]. Confirmation of all isolates using ITS-PCR and the successful nature of this measurement underscores the effectiveness of the use of molecular identification over standard morphological identification. This good concordance is in-line with the reports of[18], [19], who reported good consistency of ITS regions in identifying fungi.
In in vivo model, the infected immunosuppressed group had a significant increase in fungal burden compared to the infected group alone. This conclusion confirms that the host immune status is one of

the key determinants of the risks of invasive aspergillosis. The immunosuppression caused by cortisone must have compromised the functionality of macrophage and neutrophils vital in eliminating inhaled conidia [20] made similar observations and showed that the defective natural immunity promotes the germination of fungi and the invasion of hyphae in lung tissue[21].

This interpretation is also supported by the cytokine profile. There was a high level of IL-6 in infected mice, especially in the group of immunosuppressed mice, which is a good sign of a pro-inflammatory reaction[22]. It is established that IL-6 is central in acute phase responses and is usually linked to severity of the disease in fungal infections[23], [24]. Meanwhile, the rise of IL-10 indicates that anti-inflammatory pathways are activated an effort to decrease tissue damage. Such a response is due to an imbalance of pro- and anti-inflammatory processes, which can be the cause of disease progression. The results consistent with other studies by[25] who explained the complicated regulation of cytokines in the fungal pathogenesis.

The positive correlation ($r = 0.81$) between the fungal burden and the IL-6 levels is strong, which means that the higher the fungal load, the stronger the process of inflammatory activation. This interaction has been well reported in invasive fungal infections, where pathogen proliferation is not controlled and causes over stimulation of the immune system, and tissue destruction.

The histopathological examination of the lung tissue showed a progressive disease process of lung injury, which included mild inflammatory infiltration to severe necrosis and structural destruction. In progressive cases, fungal hyphae in the lung tissue is a positive confirmatory test of invasive aspergillosis. These results are in line with classical descriptions of the disease, in which hyphae invasion causes vascular damage, hemorrhage, and necrosis. A comparable pathologic presentation has been reported in the literature by[26], which demonstrates the damaging aspect of Aspergillus infections in people with a weakened immune system[27].

Notably, the concomitant state of infection and immunosuppression caused the worst consequences in all the parameters measured, such as fungal burden, cytokine levels, and tissue damage. This highlights the clinical importance of the model because immunocompromised patients (those with chemotherapy or corticosteroid treatments) are at a much greater risk of developing invasive aspergillosis[28], [29].

Although this study has a number of strengths such as its integrated experimental design, there are certain limitations that should be noted. Only two cytokines were considered (IL-6 and IL-10) but other immune mediators, including TNF-a, IFN-g, and IL-17 could be significant factors as well. Also, more species-level identification might be possible through molecular sequencing other than ITS-PCR.

Finally, this paper has shown that immunosuppression is a major risk factor that predisposes individuals to pulmonary aspergillosis by increasing fungal load, cytokine deregulation, and severe histopathological injuries. The results are valuable information on the pathogenesis of the disease, and they can be used to develop better diagnostic and treatment approaches.

Conclusion

This paper shows that immunosuppression is a major factor that predisposes patients to pulmonary aspergillosis due to its impact on amplifying fungal load and disturbing immune functions. The high concentration of IL-6 and IL-10 indicates an unbalanced inflammatory condition related to disease severity. Histopathological observations proved the existence of progressive lung damage, especially in infected immunosuppressed mice. In general, fungal growth and immune dysregulation are major factors of disease development, which makes it important to diagnose the disease as early as possible and develop specific treatment plans.

REFERENCES

[1] M. G. Bocci et al., "Pulmonary aspergillosis in immunocompromised critically ill patients: Prevalence, risk factors, clinical features and diagnosis—A narrative review," *Journal of Fungi*, vol. 11, no. 9, Art. no. 617, 2025.

[2] A. Casadevall, "Immunity to invasive fungal diseases," *Annual Review of Immunology*, vol. 40, pp. 121–141, 2022.

[3] L. Huang et al., "Novel diagnostic marker interleukin-33 for invasive pulmonary aspergillosis in acute-on-chronic liver failure: A proof-of-concept prospective study," *Infectious Diseases and Therapy*, vol. 15, no. 2, pp. 561–576, 2026.

[4] Q. Xie et al., "Gut-derived short-chain fatty acids and macrophage modulation: Exploring therapeutic potentials in pulmonary fungal infections," *Clinical Reviews in Allergy & Immunology*, vol. 66, no. 3, pp. 316–327, 2024.

[5] V. Sekhawat, "A histopathological approach to diagnosis and classification of invasive fungal infections," *Diagnostic Histopathology*, vol. 30, no. 10, pp. 554–563, 2024.

[6] M.-P. Ledoux and R. Herbrecht, "Invasive pulmonary aspergillosis," *Journal of Fungi*, vol. 9, no. 2, Art. no. 131, 2023.

[7] X. Chen et al., "Constructing the active surface soil layer with ZVI-biochar amendment for simultaneous immobilization of As and Zn in both contaminated soil and groundwater: Continuous versus intermittent infiltration mode," *Journal of Hazardous Materials*, vol. 445, Art. no. 130518, 2023.

[8] P. Pysarenko et al., "Using of probiotics and associated formation water as a basic fertiliser," *Journal of Ecological Engineering*, vol. 26, no. 5, pp. 301–309, 2025.

[9] American Public Health Association, *Standard Methods for the Examination of Water and Wastewater*, 6th ed. Washington, DC, USA: American Public Health Association, 1926.

[10] H. L. Barnett and B. B. Hunter, *Illustrated Genera of Imperfect Fungi*, 1972.

[11] A. H. Hendi and A. M. Al-Araji, "Isolation and identification of dermatophyte species from Iraqi patients using PCR-ITS regions," *Iraqi Journal of Science*, pp. 1550–1559, 2025.

[12] Clinical and Laboratory Standards Institute (CLSI), *Reference Method for Broth Dilution Antifungal Susceptibility Testing of Filamentous Fungi*, Approved Standard, 2nd ed., CLSI document M38-A2, vol. 28, no. 16, 2008, pp. 1–35.

[13] V. R. Poester et al., "Antifungal activity of diphenyl diselenide alone and in combination with itraconazole against *Sporothrix brasiliensis*," *Medical Mycology*, vol. 57, no. 3, pp. 328–331, 2019.

[14] J. Frank, "Advances in the field of single-particle cryo-electron microscopy over the last decade," *Nature Protocols*, vol. 12, no. 2, pp. 209–212, 2017.

[15] R. M. Chadwin, C. L. Heath, and R. W. Merkley, "A public records review of cadaver and terminal animal use in US and Canadian veterinary schools," *Journal of Veterinary Medical Education*, vol. 52, no. 6, pp. 759–772, 2025.

[16] W. Pawlina and M. H. Ross, *Histology: A Text and Atlas: With Correlated Cell and Molecular Biology*. Philadelphia, PA, USA: Lippincott Williams & Wilkins, 2018.

[17] Q. N. Nji, O. O. Babalola, and M. Mwanza, "Soil *Aspergillus* species, pathogenicity and control perspectives," *Journal of Fungi*, vol. 9, no. 7, Art. no. 766, 2023.

[18] T. J. White et al., "Amplification and direct sequencing of fungal ribosomal RNA genes for phylogenetics," in *PCR Protocols: A Guide to Methods and Applications*, 1990, vol. 18, no. 1, pp. 315–322.

[19] E. O. Olumuyiwa et al., "Morphological and molecular identification of fungi isolated from spoilt apples in Ota metropolis," *BMC Microbiology*, vol. 25, no. 1, Art. no. 360, 2025.

[20] J.-P. Latgé, "*Aspergillus fumigatus* and aspergillosis," *Clinical Microbiology Reviews*, vol. 12, no. 2, pp. 310–350, 1999.

[21] J. Furlong-Silva and P. C. Cook, "Fungal-mediated lung allergic airway disease: The critical role of macrophages and dendritic cells," *PLOS Pathogens*, vol. 18, no. 7, Art. no. e1010608, 2022.

[22] A. A. Al-Qahtani, F. S. Alhamlan, and A. A. Al-Qahtani, "Pro-inflammatory and anti-inflammatory interleukins in infectious diseases: A comprehensive review," *Tropical Medicine and Infectious Disease*, vol. 9, no. 1, Art. no. 13, 2024.

[23] M. S. Lionakis, R. A. Drummond, and T. M. Hohl, "Immune responses to human fungal pathogens and therapeutic prospects," *Nature Reviews Immunology*, vol. 23, no. 7, pp. 433–452, 2023.

[24] M. U. Obaji, A. N. Oli, and M. C. Ugwu, "The roles of IL-6, IL-8, and TNF-α in pediatric immune defense and infection severity," *OBM Genetics*, vol. 9, no. 2, pp. 1–28, 2025.

[25] L. Romani, "Immunity to fungal infections," *Nature Reviews Immunology*, vol. 11, no. 4, pp. 275–288, 2011.

[26] M. Kousha, R. Tadi, and A. Soubani, "Pulmonary aspergillosis: A clinical review," *European Respiratory Review*, vol. 20, no. 121, pp. 156–174, 2011.

[27] X. Zheng and K. Xu, "Diagnostic value of bronchoalveolar lavage fluid testing combined with high-resolution computed tomography of patients with invasive pulmonary fungal disease," *Journal of Radiation Research and Applied Sciences*, vol. 19, no. 1, Art. no. 102171, 2026.

[28] A. Elalouf, H. Elalouf, and A. Rosenfeld, "Modulatory immune responses in fungal infection associated with organ transplant—Advancements, management, and challenges," *Frontiers in Immunology*, vol. 14, Art. no. 1292625, 2023.

[29] S. H. Rasheed et al., "Fungal infections and their impact on cytokine dysregulation: Biomarkers of inflammation in *Histoplasma capsulatum* infections," *Academia Open*, vol. 10, no. 2, 2025, doi: 10.21070/acopen.10.2025.12854.